



Horse Hoof And Leg Anatomy: A Guided Tour

Scott J. Duggan
Livestock Extension Faculty

Today's Mission

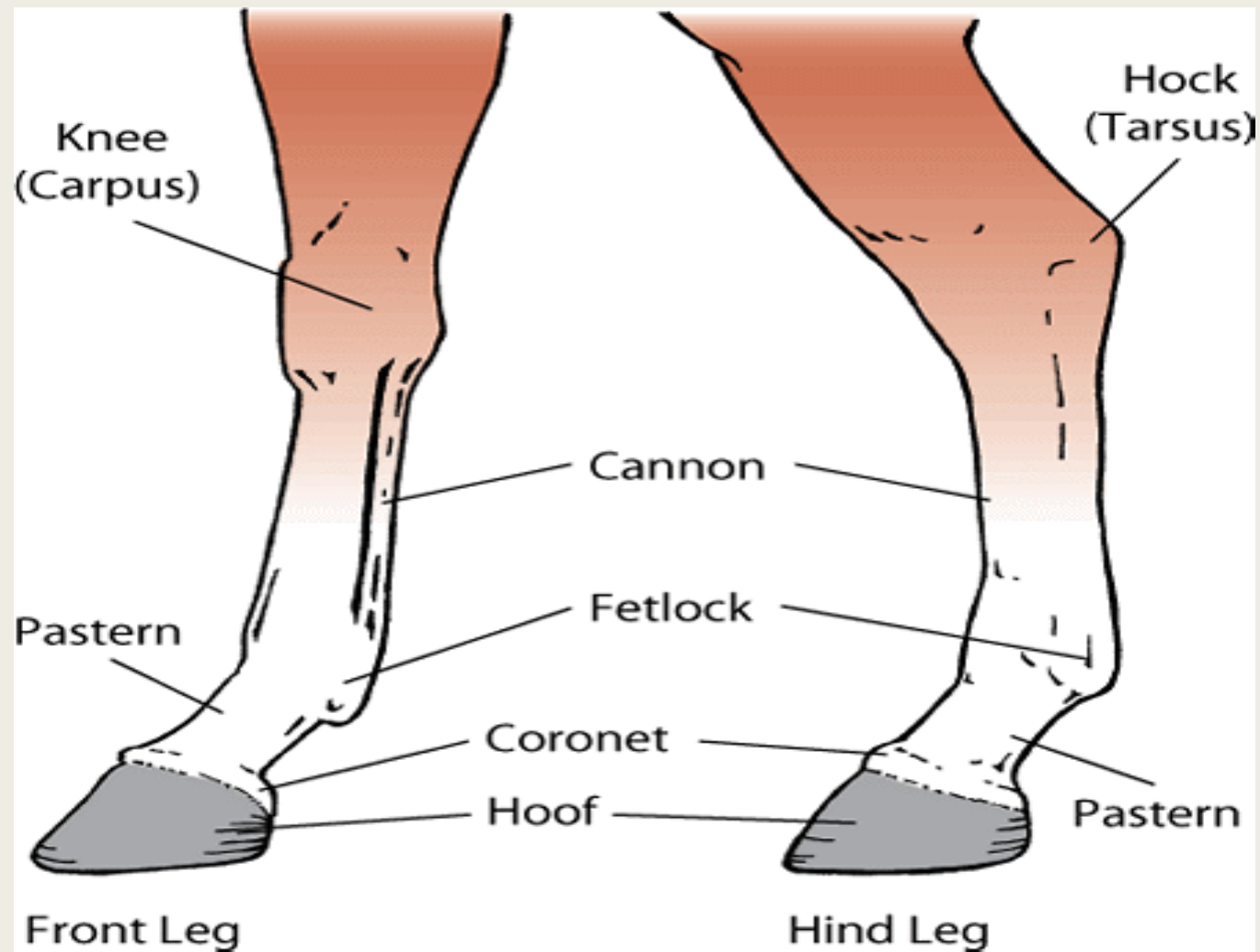
- Be able to visualize the skeletal anatomy of the lower leg and hoof of the horse.
- Develop an understanding of the causes of equine lameness and methods of treatment.



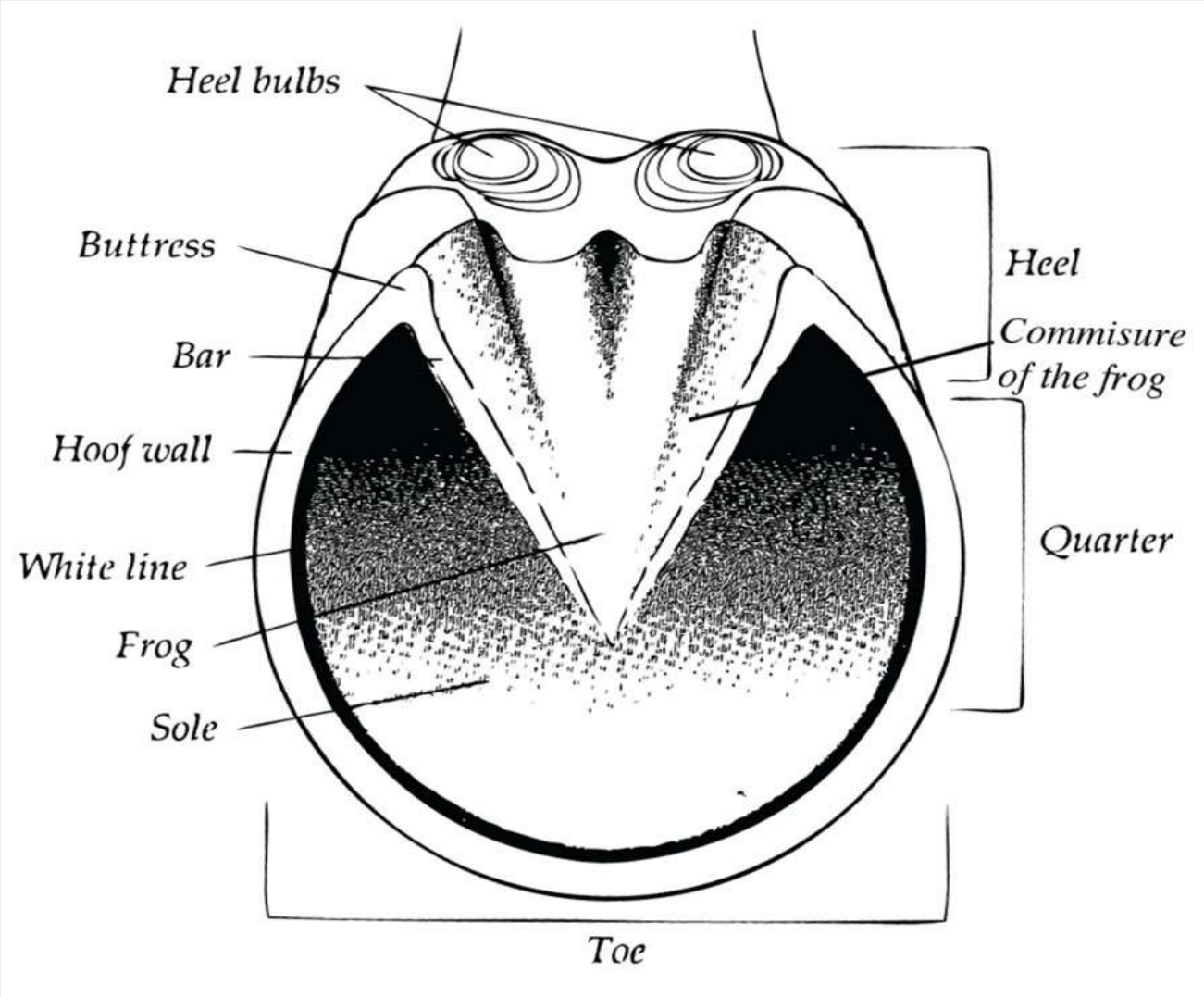
No Hoof, No Horse



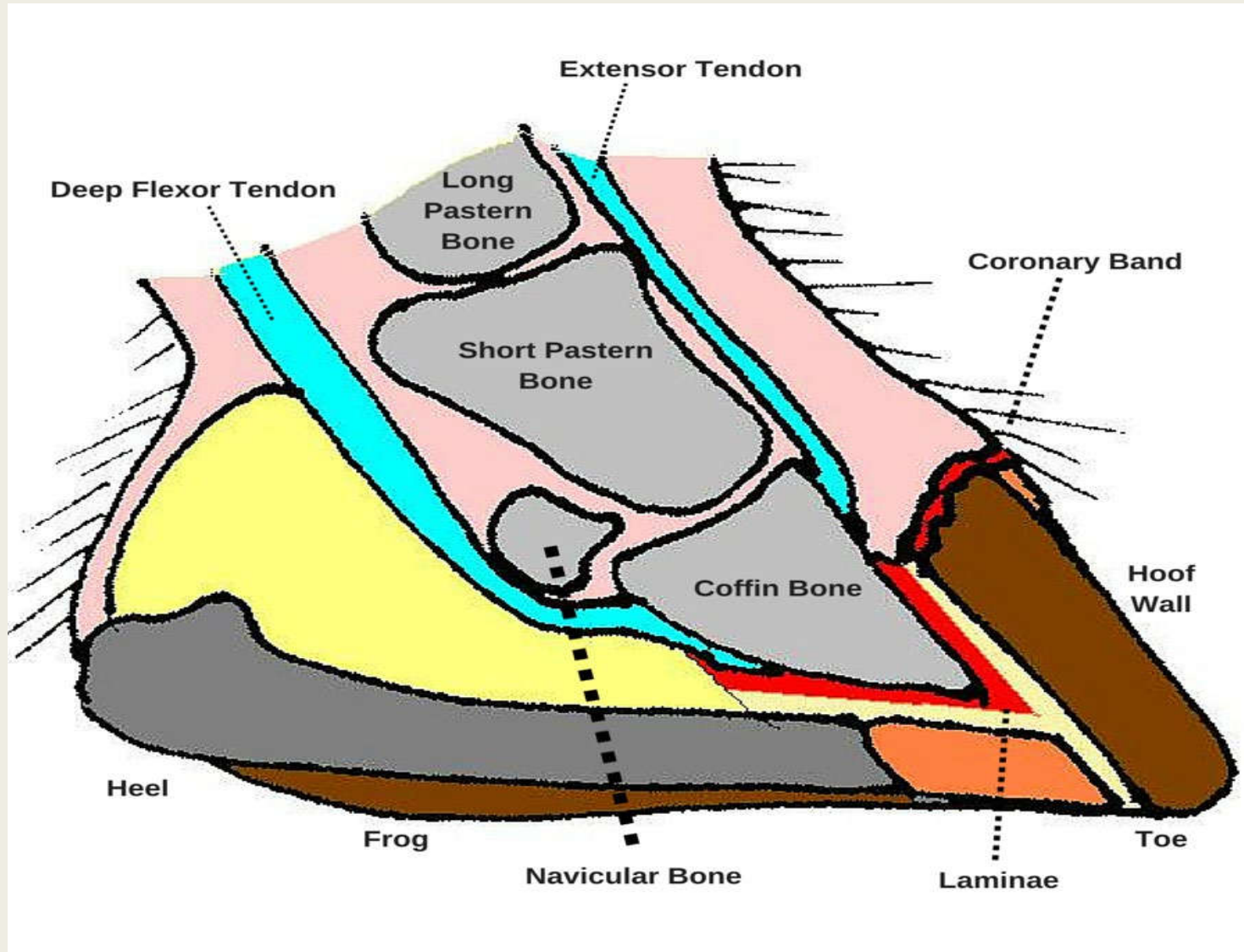
Parts of Lower Leg



Parts of the Hoof



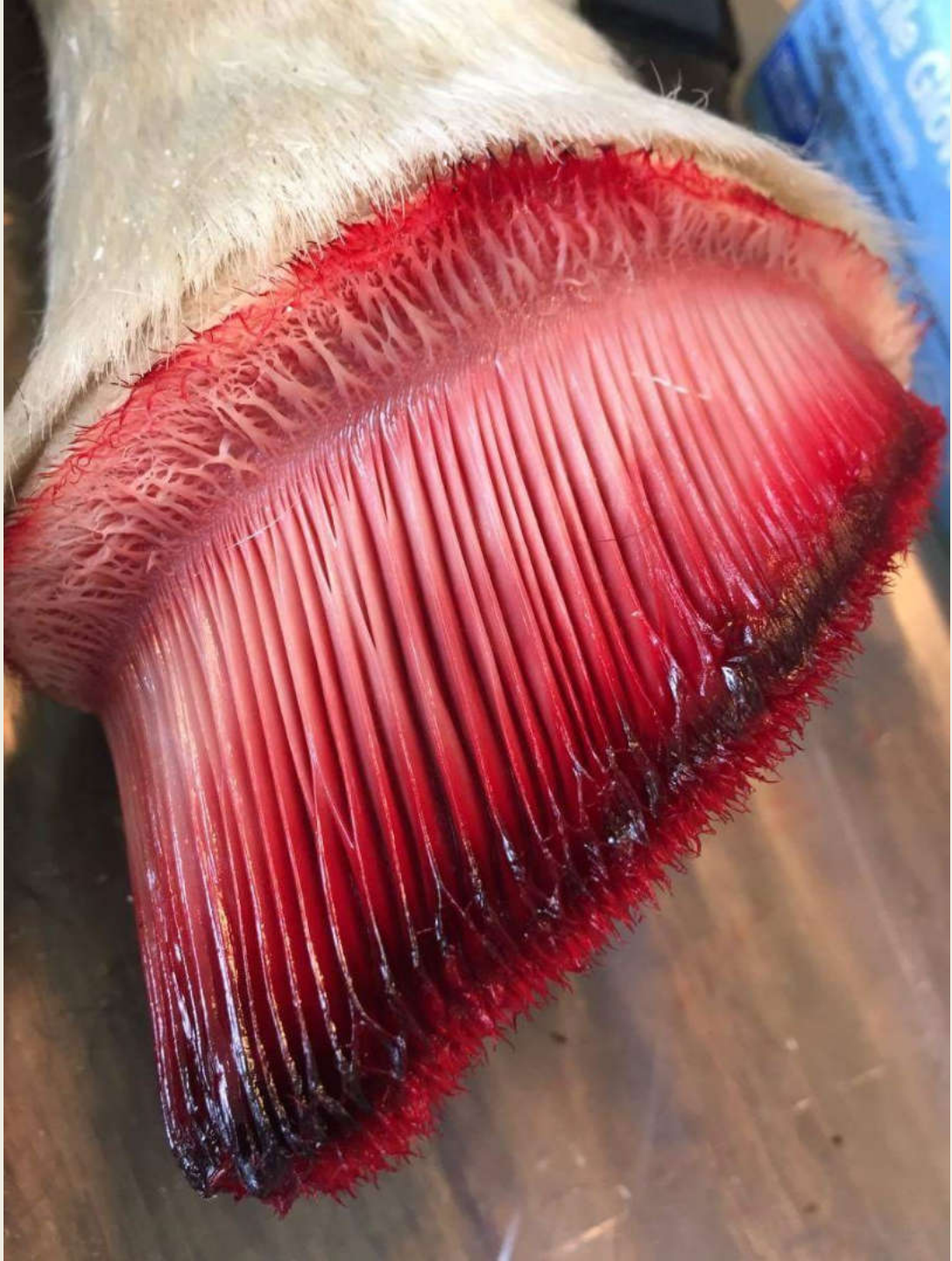Structures of Lower Leg & Hoof



How Do Horses Keep Their Shoes On?

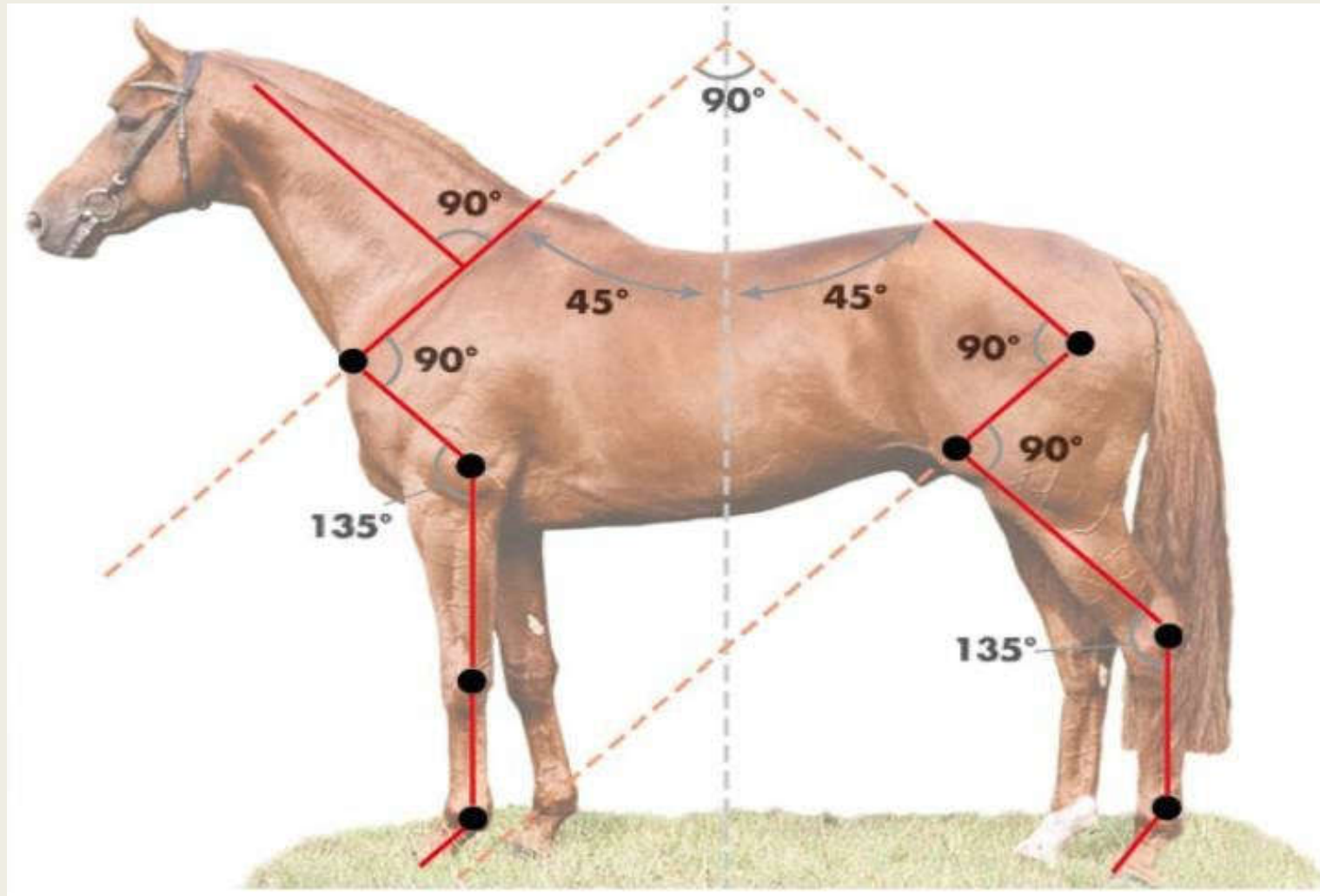


- Warning! Graphic picture ahead!



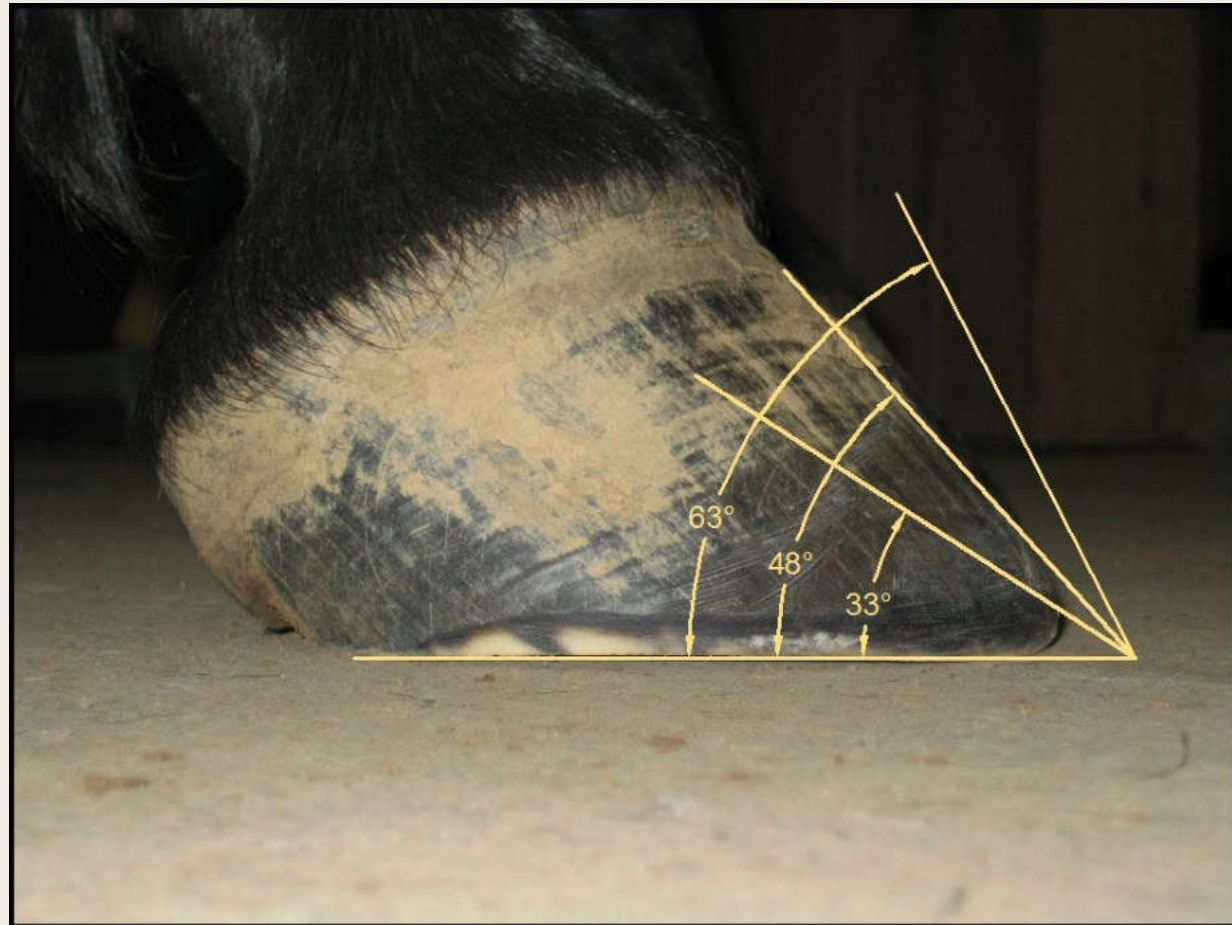

Angle of Shoulder = Pastern = Hoof Angle

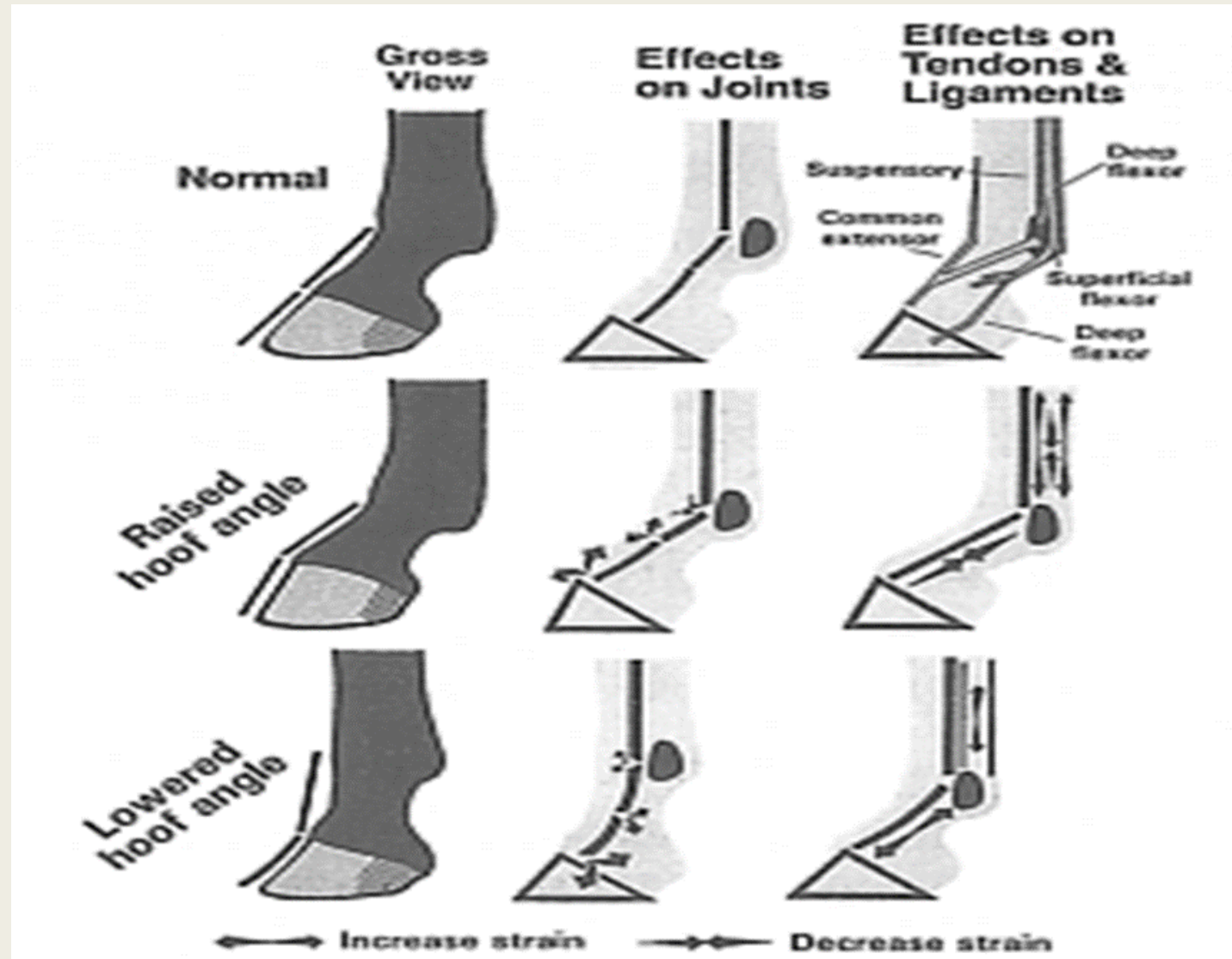


What Is The Correct Angle Of The Hoof?

- 70 degrees
- 40 degrees
- 45 degrees
- 50-54 degrees
- 52-58 degrees



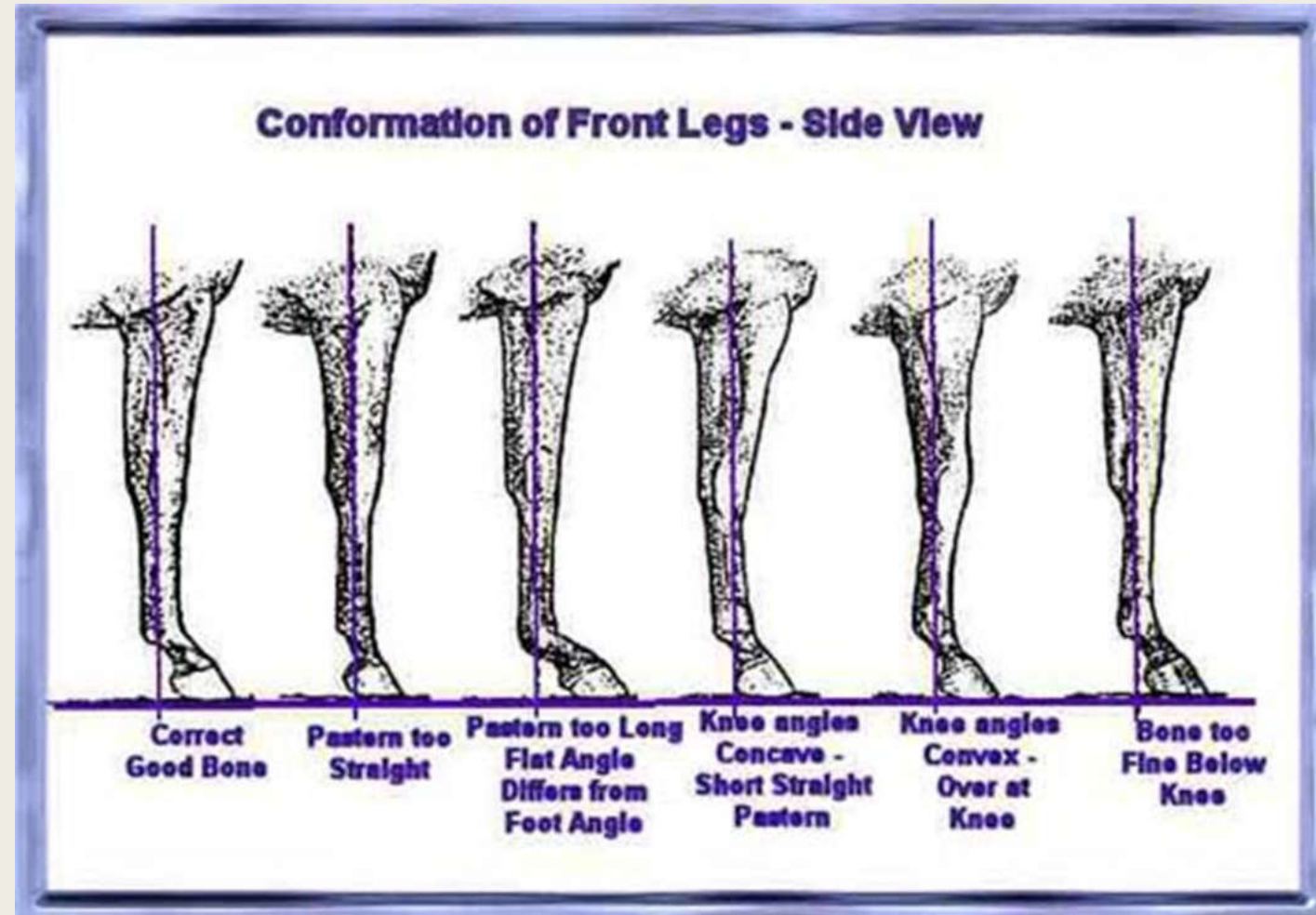
Angle of the Hoof



Angle of the Hoof - Extremely Important!



Angle of the Hoof - Extremely Important!



Lameness or Unsoundness

- An abnormality in a horse's movement caused by pain or reduced range of motion. It is commonly used interchangeably with the term unsoundness since a "sound" horse is one that is not lame.

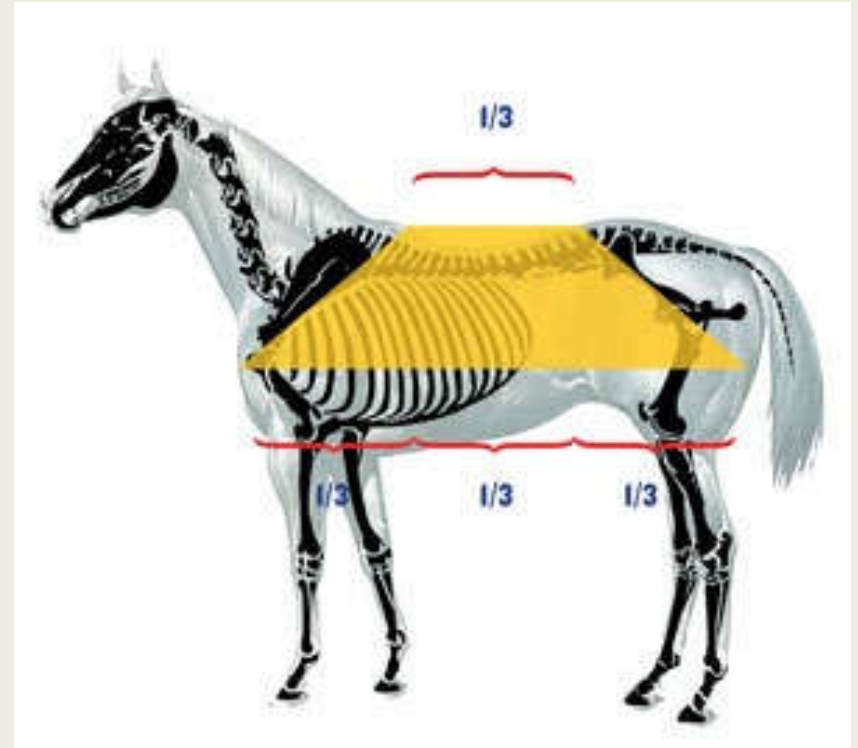

Lameness or Unsoundness

- Though often thought of as a problem of the feet or legs, lameness can involve virtually any part of the body and can originate in bone or soft tissue.

What Is The #1 Way To Prevent Lameness?



#1 way to prevent lameness is to purchase a horse with good conformation



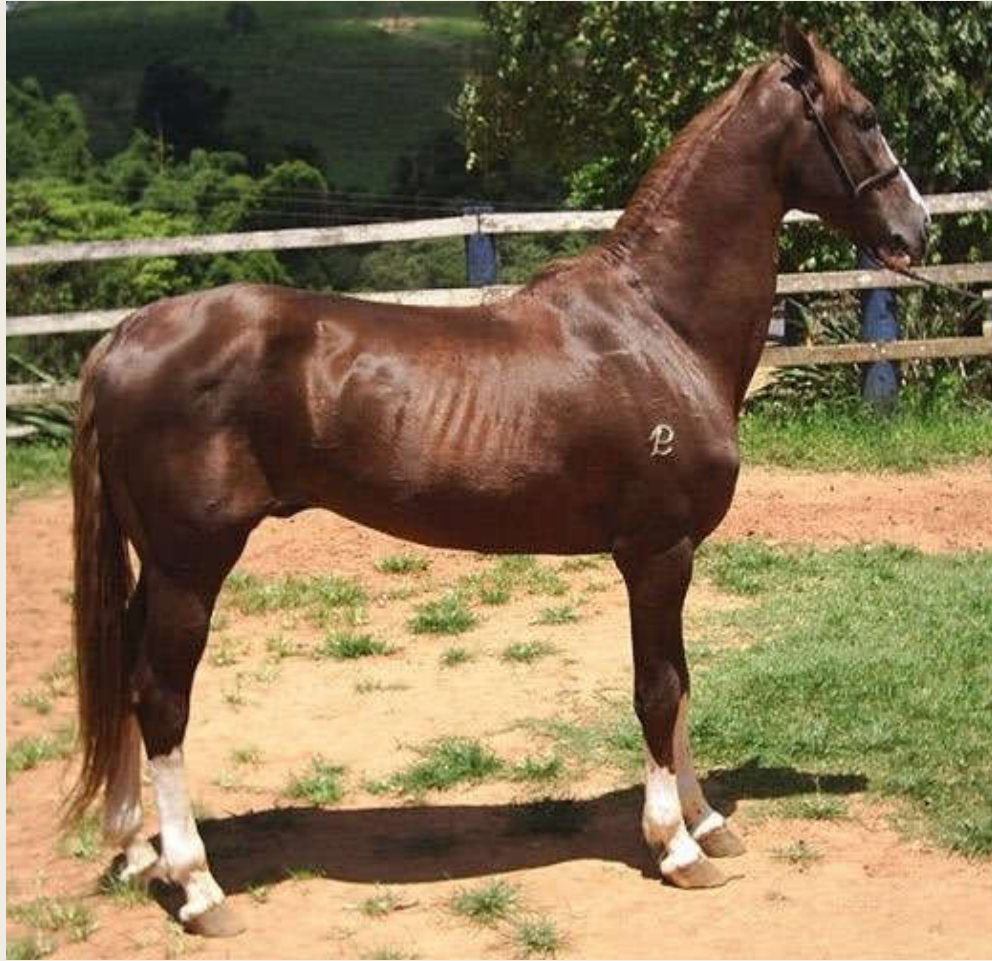Balanced Horse




Balance Required



Lameness Waiting to Happen



Lameness Waiting to Happen



Five Common Causes of Equine Lameness

- Traumatic injuries: Sprains, strains, fractures and other injuries to the musculoskeletal system including bones muscles, cartilage, tendons, ligaments and joints; damage to the nervous system including the brain, spinal cord, and nerves
- Degenerative diseases: Arthritis, degenerative joint disease, osteoarthritis
- Foot related injuries, infections and diseases
- Diet related diseases: laminitis (founder), azoturia (tying up), developmental orthopedic diseases (DOD)
- Limb deformities: angular limb deformities and flexural limb deformities

The Lameness Scale

- The American Association of Equine Practitioners has developed a grading scale (0-5) so that all horsemen and veterinarians can use the same criteria for describing a lameness.
- Grade 0: A sound horse .
- Grade 1: Lameness that is difficult to observe and is not consistently apparent.
- Grade 2: Lameness that is difficult to observe at a walk or when trotting in a straight line, but consistently apparent under certain circumstances.
- Grade 3: Lameness that is consistently observable at a trot under all circumstances.
- Grade 4: Lameness that is obvious at the walk.
- Grade 5: Lameness that produces minimal weight bearing in motion and/or at rest, or a complete inability to move.

How Do I Tell if Skippy is Lame?

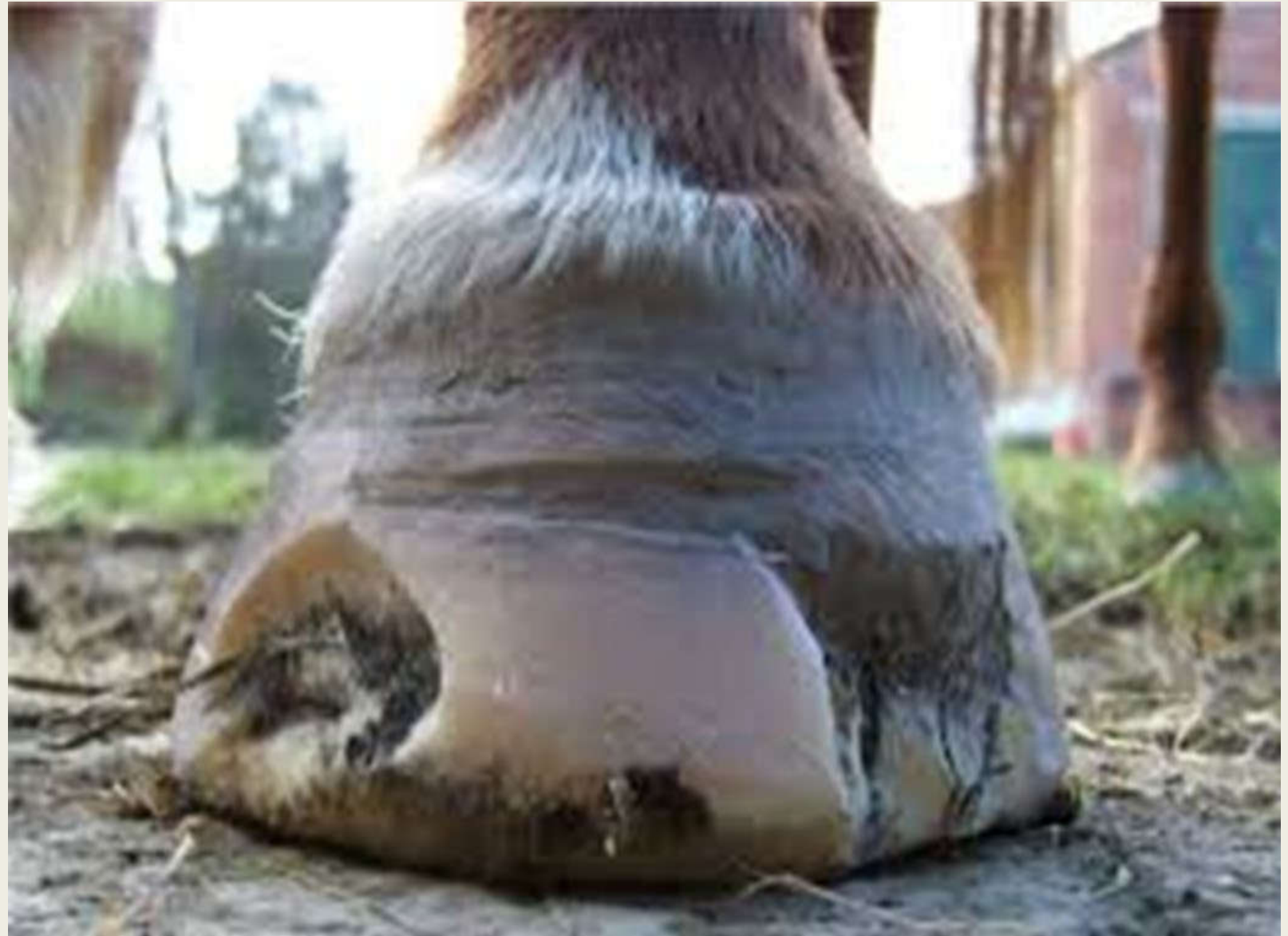- Head-bob: Horse's head bobs UP when a sore FORE limb hits the ground.
- His head bobs DOWN when a sore HIND limb hits the ground.
- Tip: A head-bob is easiest to see when your horse is trotting toward you.
- As a general rule, the more pronounced the bob, the more severe the pain.
- Not sure if a horse is lame? Trot horse in a circle and stress of circle will cause horse to limp.

What is This?



Thrush

- Anaerobic bacterial infection of the frog and commissure groove.
- Cause: Unsanitary conditions and poor hoof care.
- Trim away infected parts, irrigate with 7% iodine or bleach & water combination. Air kills anaerobic bacteria.
- Clean hoof and paddock daily.
- Severe cases may require packing with medication and padding the hoof.
- Tetanus shot should be current.



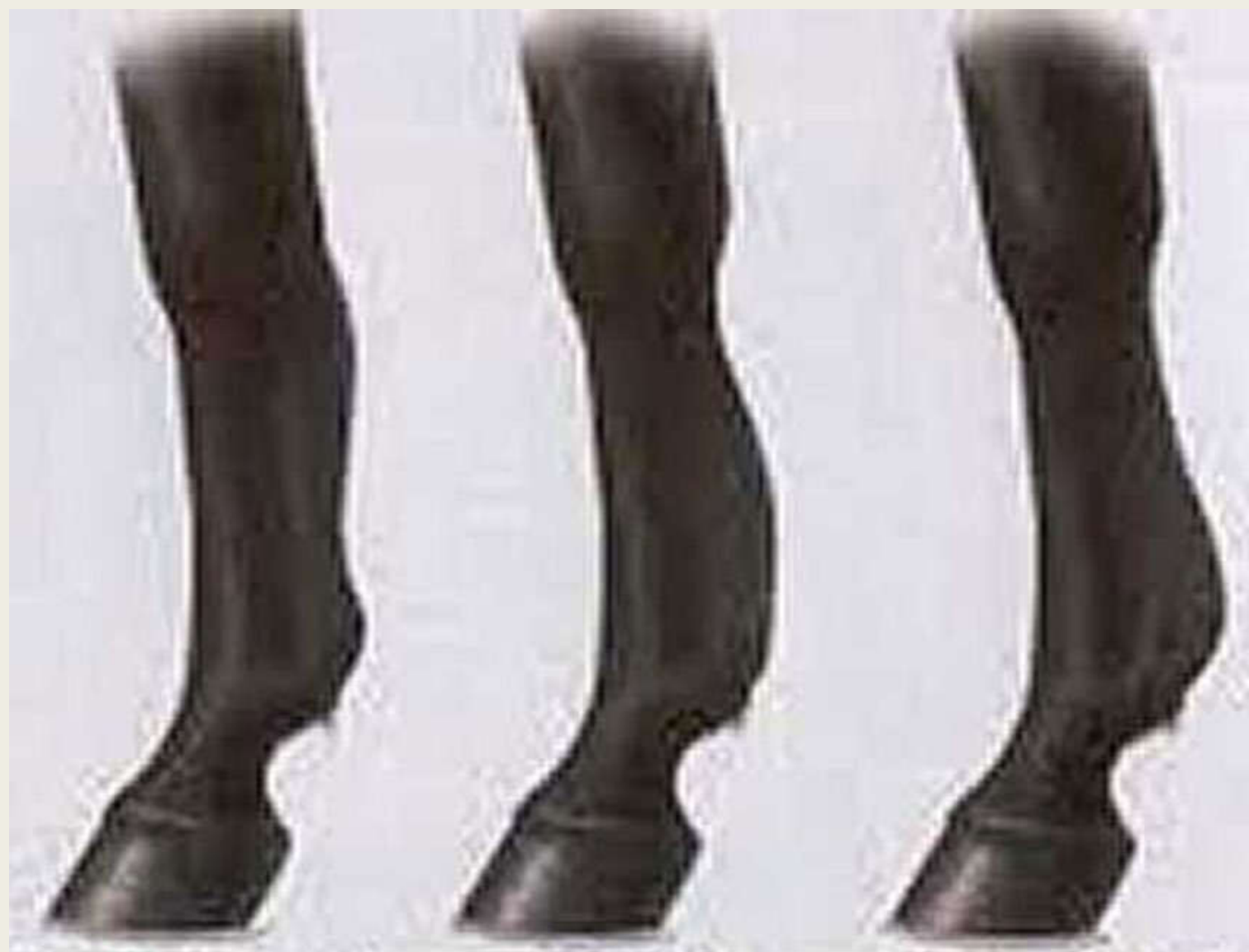Abscess - An infection of the sensitive tissues of the hoof

- Cause: Rocks, deep bruising of the sole, nails, and/or sharp objects that puncture sensitive tissue of the hoof.
- Abscesses will follow the path of least resistance.
- Sometimes puncture hole may be seen (black spot).
- The leg may be hot and swollen.
- Call a vet if not experienced!



What Lameness Typically Plagues Racehorses?






**High Bowed
Tendon**

**Middle
Bowed Tendon**

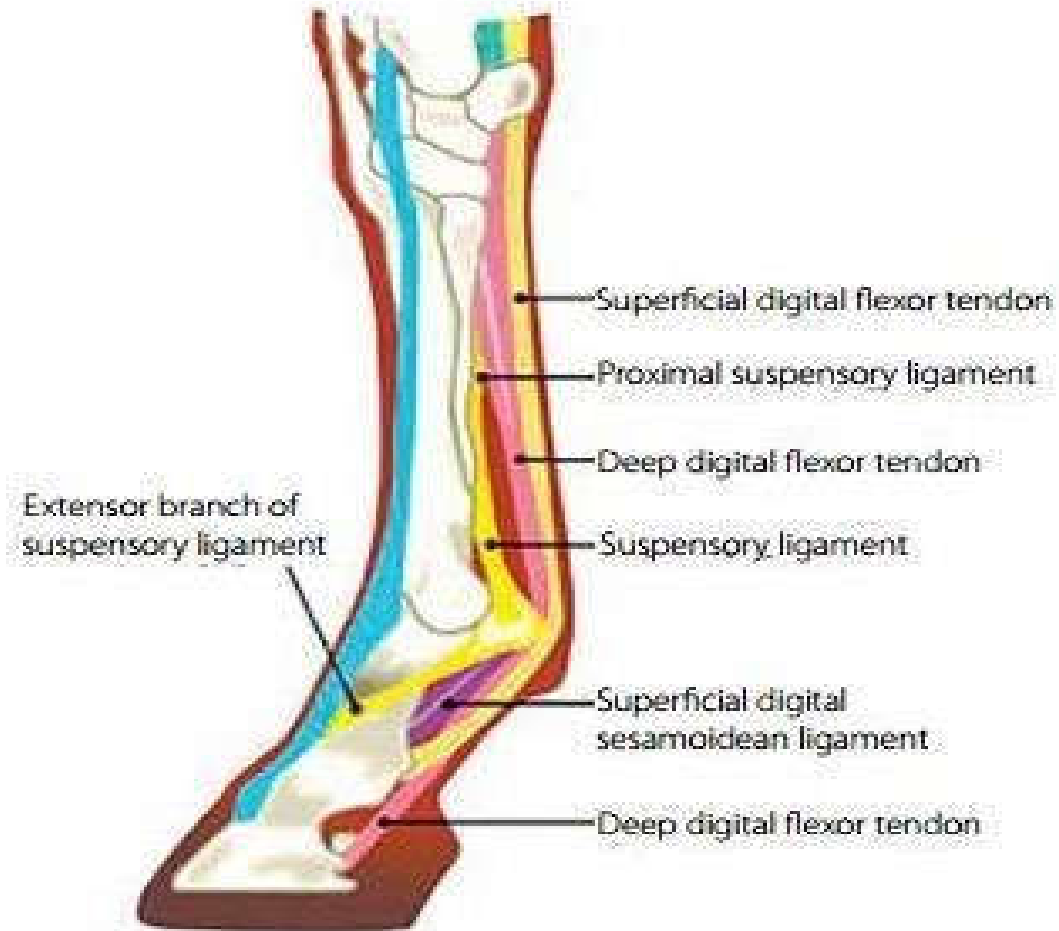
**Low Bowed
Tendon**

Bowed Tendon

- Thickening of the back surface of the leg immediately above the fetlock.
- Superficial flexor tendon, deep flexor tendon, & suspensory ligament.
- Causes – Severe strain, under-sized tendons, age.




Support Structure Lower Limb




ABOVE: Normal anatomy of the lower limb of the equine.

Bowed Tendon

- Lots of rest!
- Initial treatment of a bowed tendon should concentrate on anti-inflammatory therapies, including cold water or ice therapy.
- Anti-inflammatory medications on the direction of a veterinarian.
- The horse should be confined to a small area until the severity of the injury can be assessed with ultrasound.



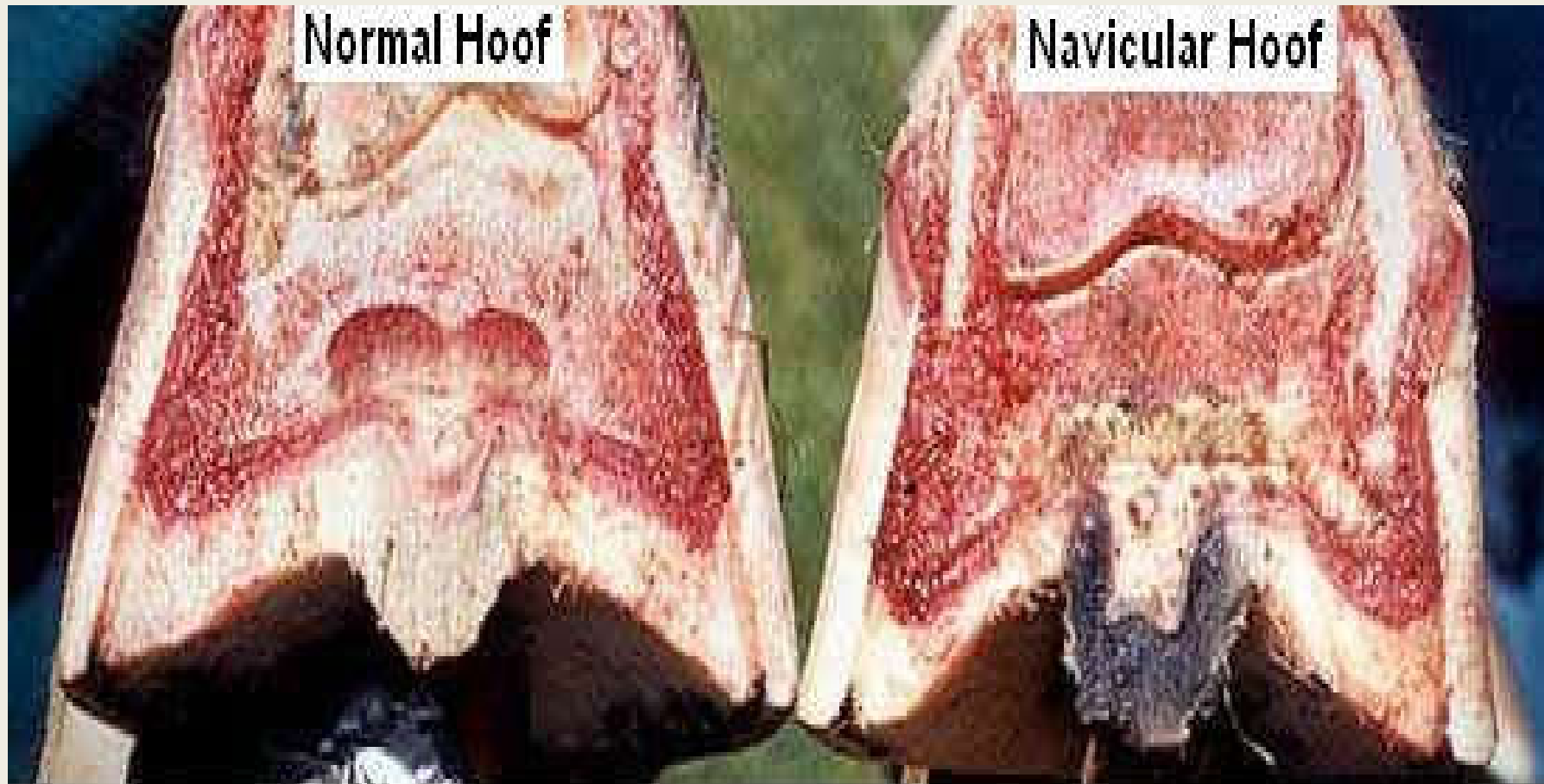


Contracted Heels - Horse develops narrow heels that do not expand properly.

■ Caused by:

- Improper shoeing, trimming, leaving feet long, genetics.
- Cured by proper trimming/shoeing.
- Leaving horse bare foot may not always be the answer.



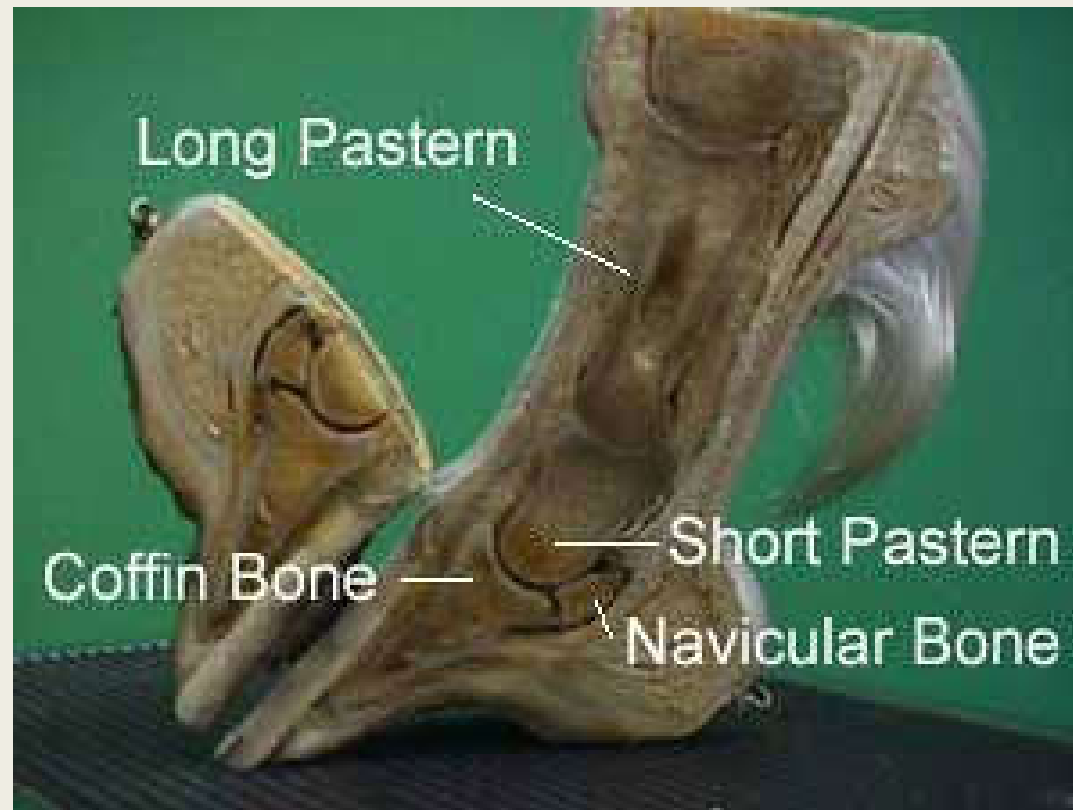

Note the contracted width, dead frog, necrotic tendon and damage due to the chronic inflammation for the hoof afflicted with navicular syndrome. Age 17

Navicular

- Inflammation of navicular bone and/or bursa.
- The blood supply to and/or from the navicular bone is disrupted.
- Degenerative disease, similar to arthritis.
- It is likely that abnormal biomechanical stresses are the basis for the disease.
- Performance horses tend to suffer from this degenerative disease.

The Role of the Navicular Bone – Acts as a fulcrum for the deep digital flexor tendon



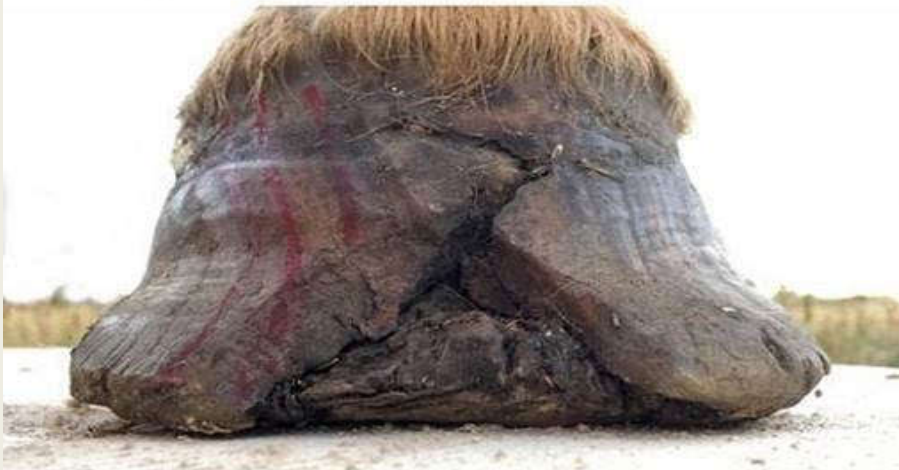Navicular

- Lesions on the navicular bone, as well as bone edema (bruising), are often found in lame horses, but they are also seen in plenty of horses who are perfectly sound.

Navicular

- Hard work, upright pasterns, small feet, trimming the heels too low.
- Special shoeing may help.
- Pain alleviation with drugs is an option.
- Nerving the horse (typically last resort).

Trim by Anne Schuite



20 July - before trim



20 July - after trim



29 September - after trim



10 January - after trim

White Line Disease

- A condition in which opportunistic organisms enter and infect any separation in the hoof wall—can range from mild to severe (shown).
- More common in humid climates.
- There are occasional instances where drought conditions might elicit cracks or an opening along the white line, allowing organisms to access the inner hoof wall.

White Line Disease

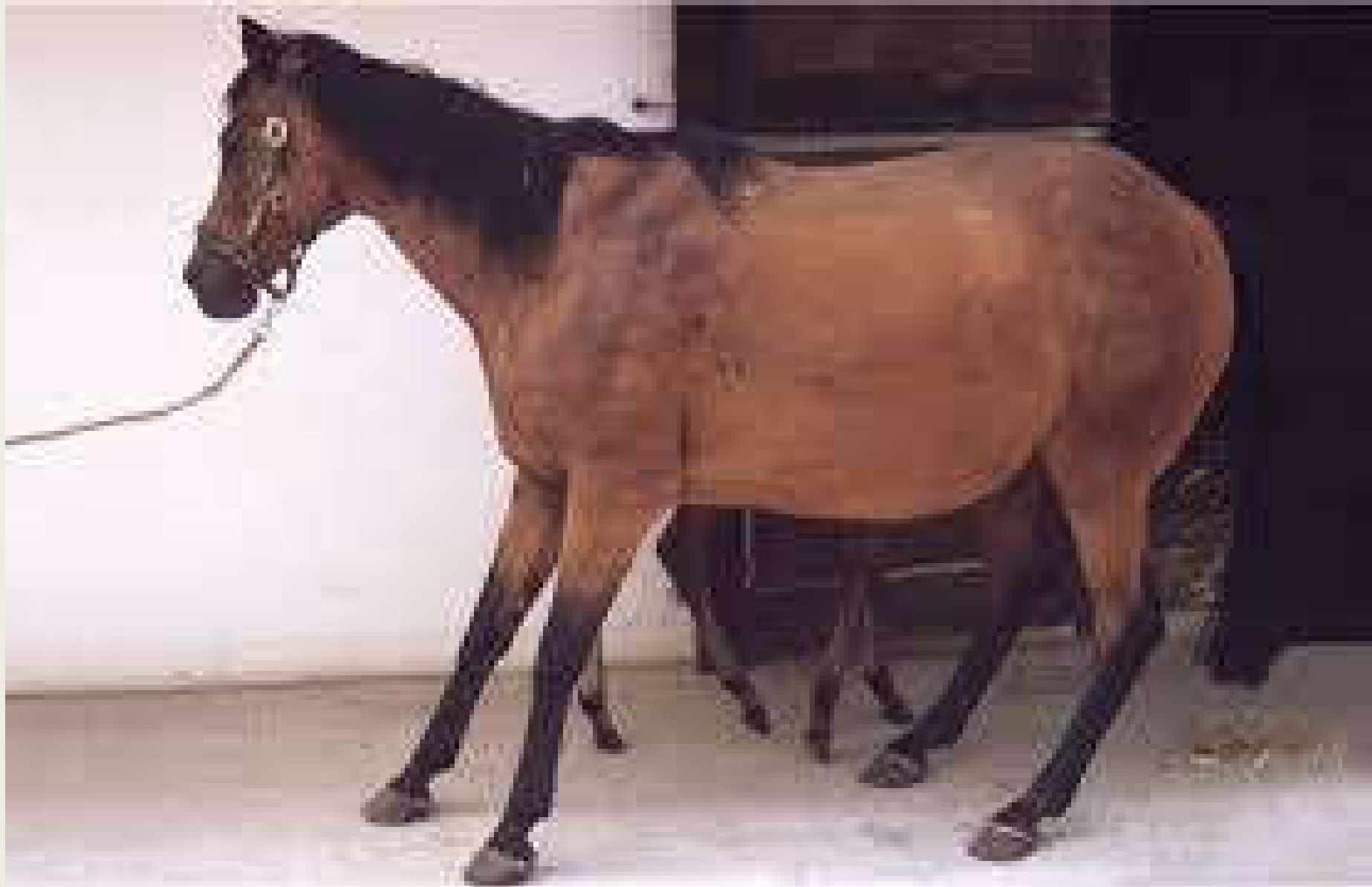- Currently, veterinarians don't completely understand why hoof wall separation occurs.
- Any hoof distortion or change in the foot's loading pattern can put the hoof wall at risk for separation.
- Examples of hoof distortions include long toe-low heels, club foot, sheared heels, and overgrown hooves.
- The condition might occur in all four feet, only one foot, or only the front and/or rear

White Line Disease Treatment

- Soaking the hoof in a chlorine-based agent once or twice a week and keeping the hoof as clean as possible is recommended.



Classic Laminitic Stance

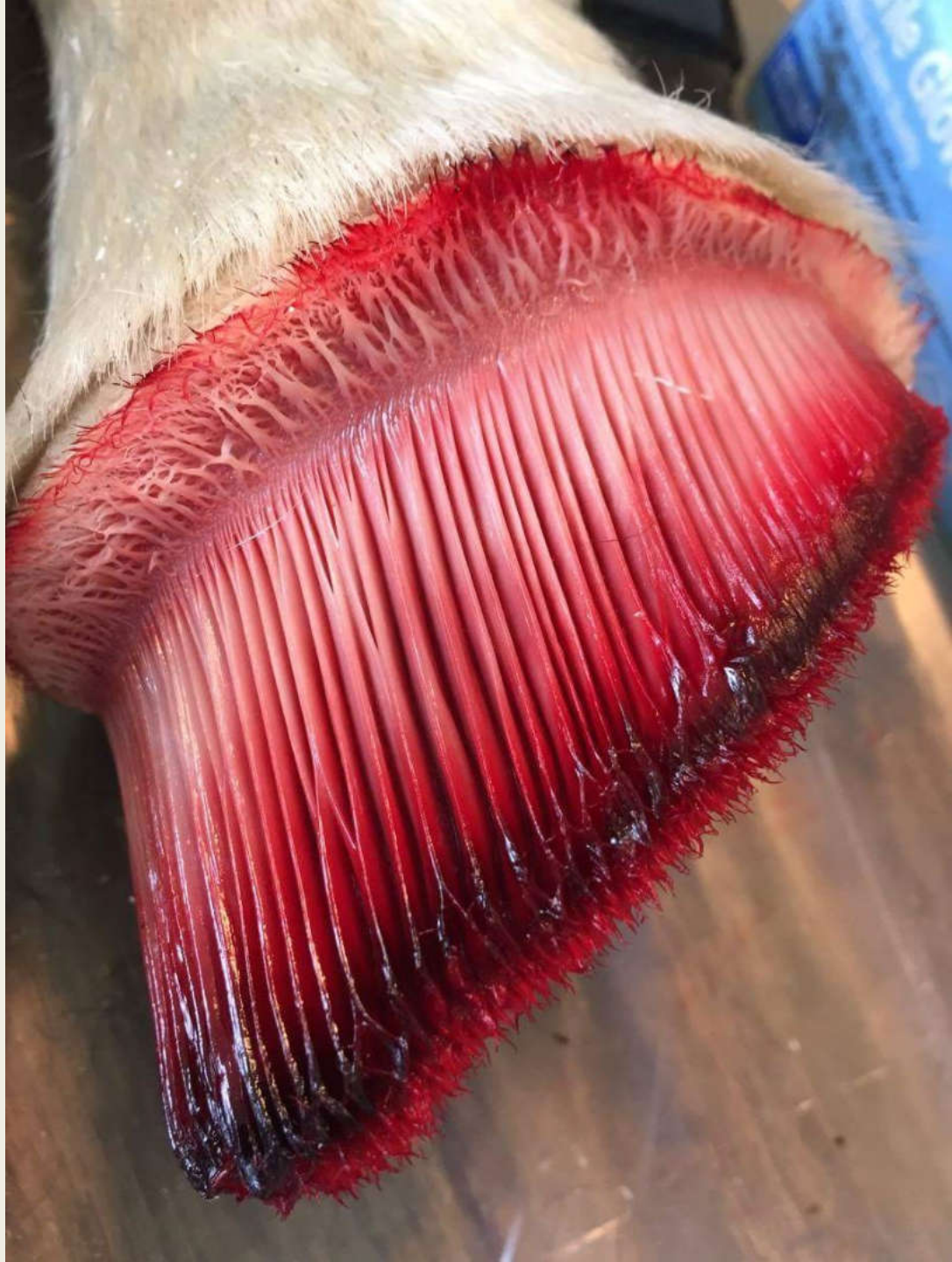

Causes of Laminitis

- High intake of soluble carbohydrates (sugars and starch).
- Stress – Standing on opposite limb for too long. (Barbaro)
- Impact or repeated concussion
- Severe infection
- Obesity-Look for hardening of crest area
- Retained placenta
- Cushing's disease

Laminitis

- Inflammation of the sensitive laminae which attach the hoof capsule to the fleshy portion of the foot.
- In laminitis, the blood flow to the laminae is affected, resulting in inflammation and swelling in the tissues within the hoof, and severe pain. As the laminae are starved of oxygen and nutrient rich blood, the cells become damaged. Unless the cause is removed and treatment is started immediately on first signs of the condition, the sensitive laminae begin to die.



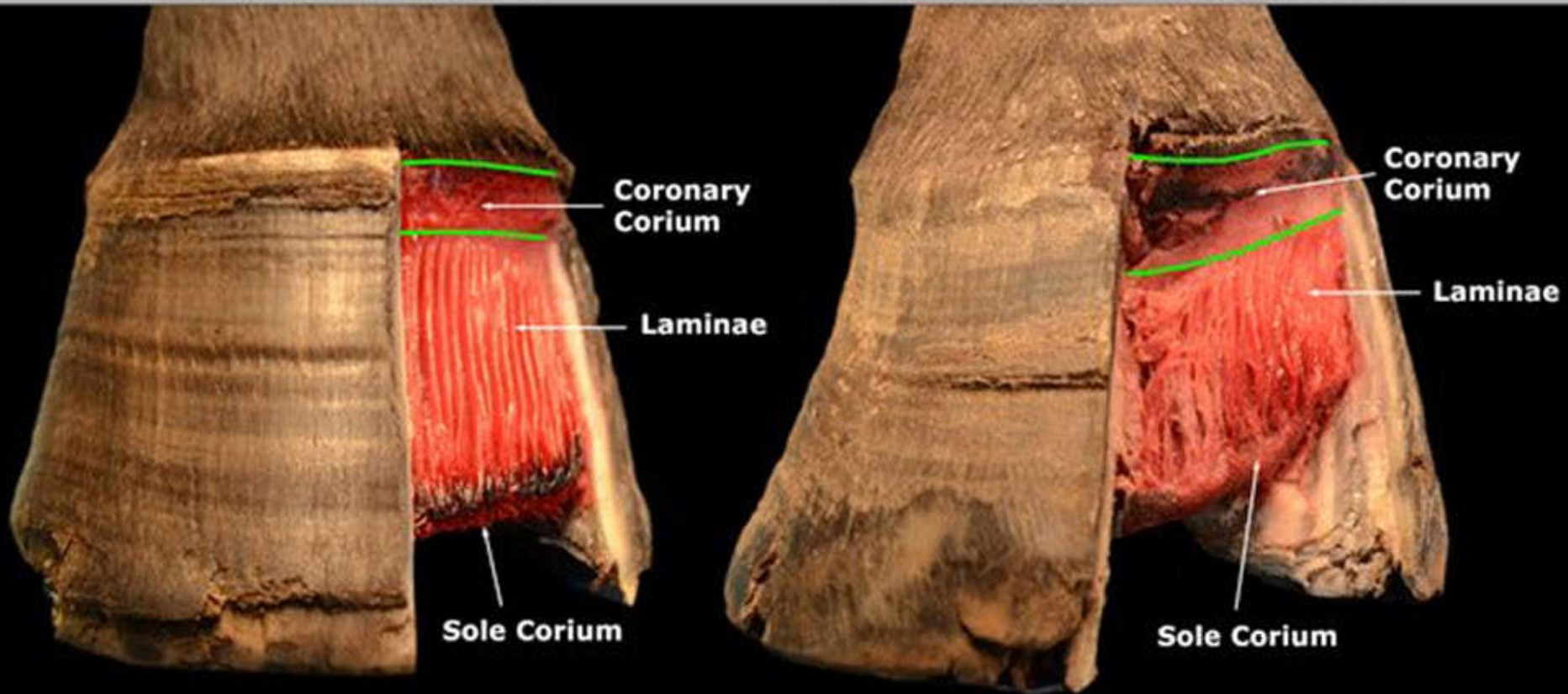
- This is a picture of the horny hoof wall from a horse. The white arrow identifies a vertical groove of horny lamina that interlocks with the sensitive lamina.



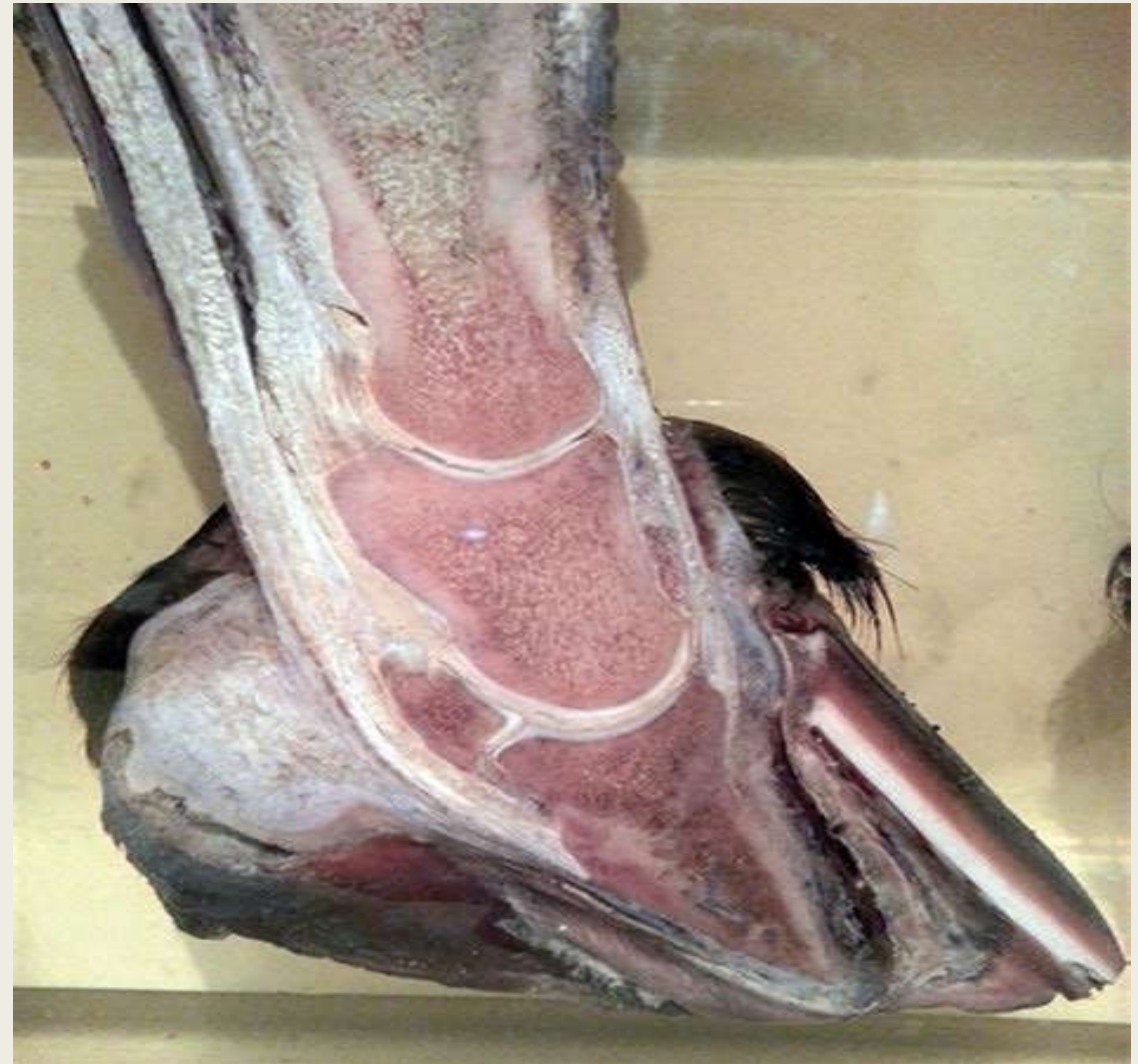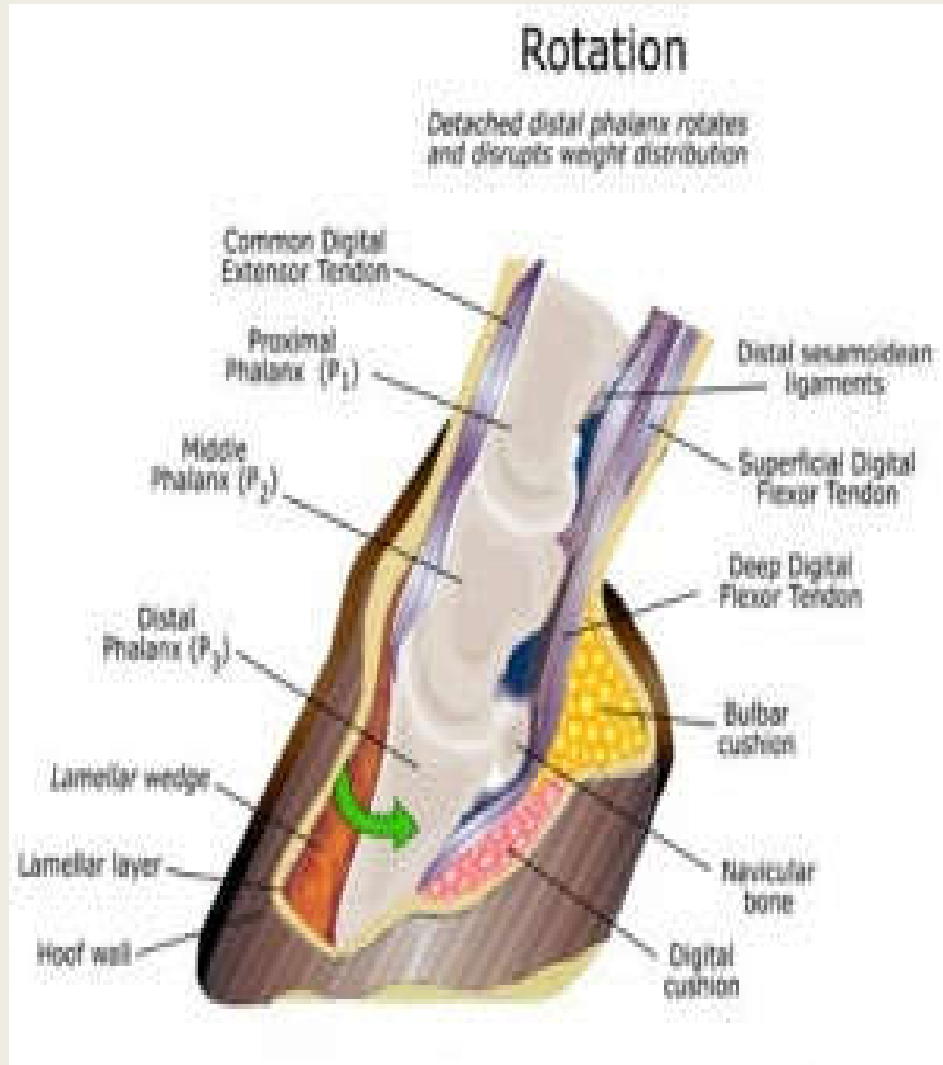
LAMINITIS

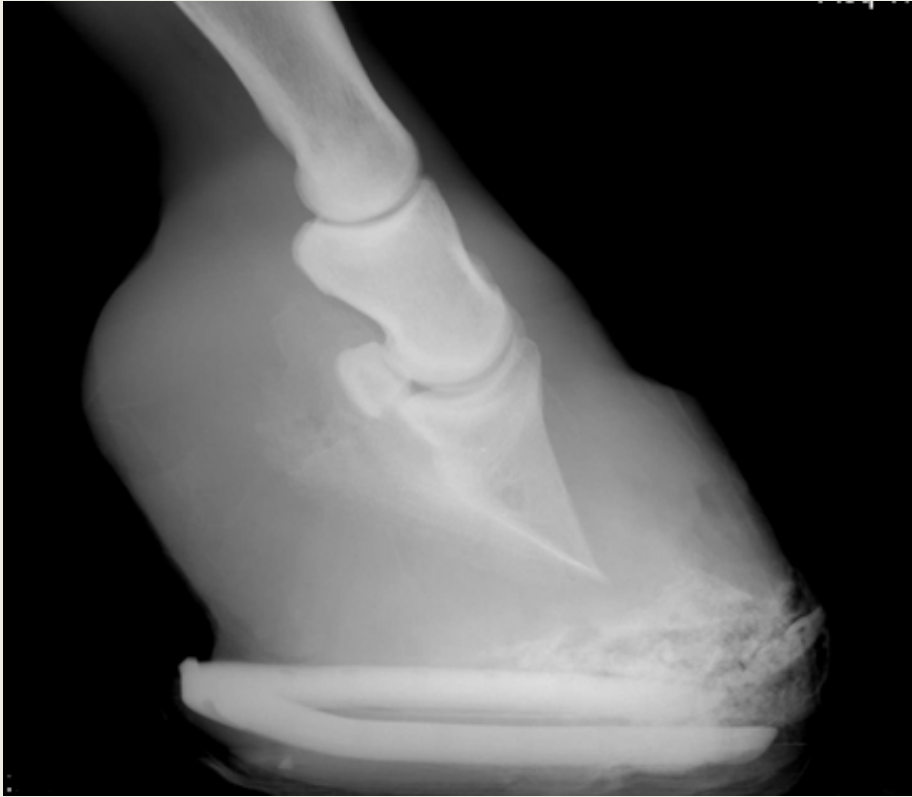Non-Laminitic Hoof

Hoof with Chronic Laminitis

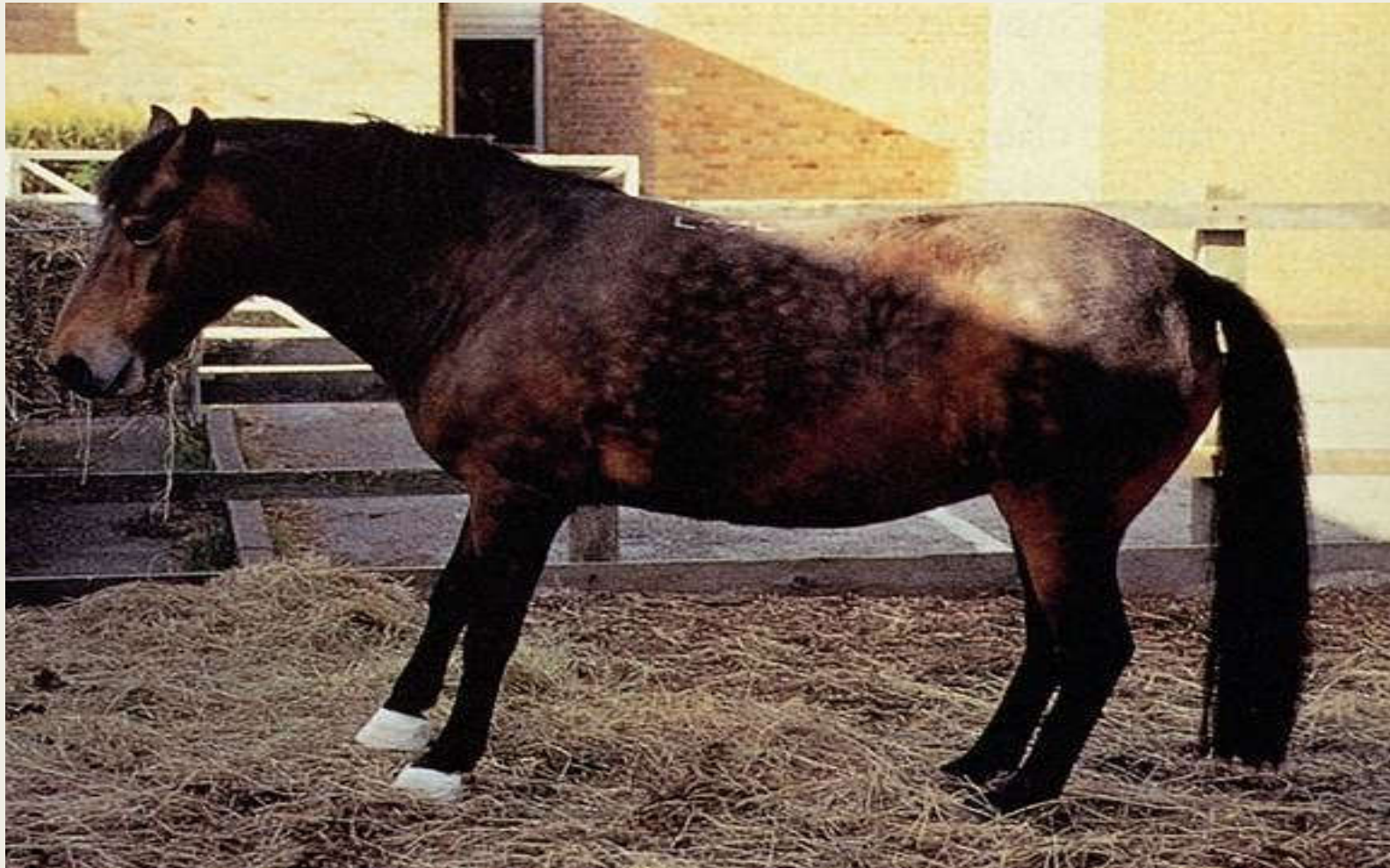

Severe Laminitis





Cresty, Hard Neck Line



Symptoms of Laminitis

- Less activity and a reluctance to move when led
- Lying down more than is normal
- Depression
- Reluctance to turn
- 'Bounding' digital pulses in affected legs. Learn how to read your horse's pulses with the fantastic iPad App or eBook shown to the right
- Blood in the white line
- Fever rings visible on hoof wall
- Pain response when pressure is applied to sole
- Standing a typical laminitic stance - hind feet further under the body with weight rocked back and front feet further out in front of the body

Treatment of Laminitis

- Can be fixed depending on the severity. Corrective shoeing to include heart bar shoe and resection of the hoof if necessary.
- Good diet – no grass pasture if that is the cause or contributor.
- Beware lush or frosted clover.
- Reduce stress
- Keep feet cool if there is heat in the area
- Pain medicine to reduce stress and increase comfort.

Today's Mission

- Be able to visualize the skeletal anatomy of the lower leg and hoof of the horse.
- Develop an understanding of the causes of equine lameness and methods of treatment.

Questions?

