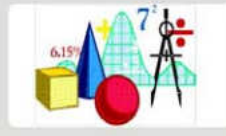




ZOOLOGY



THEORY



EXAMPLES



EXERCISES



SOLUTION & TIPS

ANIMAL TISSUE

CAREER POINT

TOTAL LEARNING SOLUTION PROVIDER

*Where **Care** leads to **Career***

ANIMAL TISSUE

INTRODUCTION ::

Tissue : A group of cells similar in structure, function and origin.

In a tissue cells may be dissimilar in structure and function but they are always similar in origin.

- Word animal tissue was coined by – **Bichat**
- N. Grew coined the term for Plant Anatomy.
- Study of tissue – **Histology**
- Histology word was given by – **Mayar**
- Father of Histology – **Bichat**
- Study of tissue is also called **Microscopic anatomy**.
- Founder of microscopic anatomy – **Marcello Malpighi**

Based on **functions & location** tissues are classified into four types :

Type	Origin	Function
1. Epithelial tissue	Ectoderm, endoderm, mesoderm	Protection, secretion, absorption etc.
2. Connective tissue	Mesoderm	Support, binding, storage, protection, circulation.
3. Muscular tissue	Mesoderm	Contraction and movement
4. Nervous tissue	Ectoderm.	Conduction and control

EPITHELIAL TISSUE ::

Word epithelium is composed of two words

Epi – Upon

Thelio – grows

A tissue which grows upon another tissue is called **Epithelium**.

- Cells are either single layered or multilayered.
- Cells are compactly arranged and there is no intercellular matrix.
- Cells of lowermost layer always rest on a non living basement membrane.
- Cells are capable of division and regeneration throughout the life.
- Free surface of the cells may have fine hair **cilia** or **microvilli** or may be smooth.
- Epithelial tissue is non-vascularised.

Due to absence/less of intercellular spaces blood vessels, lymph vessels are unable to pierce this tissue so blood circulation is absent in epithelium. Hence cells depend for their nutrients on underlying connective tissue.

Between epithelium & connective tissue, a thin non living acellular basement membrane is present which is highly permeable.

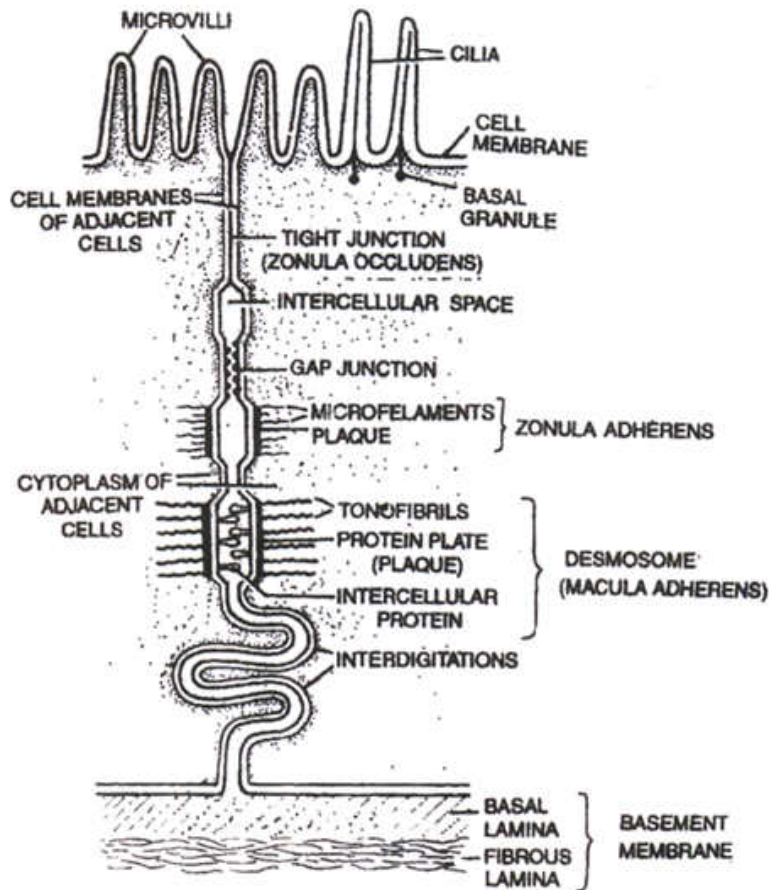
Basement membrane consist of 2 layers.

- (a) **Basal lamina** : made up of glycoprotein, and secreted by epithelium cells.
- (b) **Fibrous lamina** : Formed of collagen and reticular fibres suspended in mucopoly-saccharide which is matrix of connective tissue.

- So basement membrane is secreted by both epithelium and connective tissue.
Mucopolysaccharide is present in the form of Hyaluronic acid which is composed of 2 components–N acetyl glucosamine & glucuronic acid. Both these components are found in alternate form.
– NAG – GA – NAG –

Specialized junctions between epithelial cells : -

- To provide mechanical support for the tissue plasma membrane of adjacent epithelial cells modified to form following structures called as Intercellular Junctions.
 - **Tight junctions (Zonula occludens)** : help to prevent substances from leaking across the tissue. Plasma membranes in the apical parts become tightly packed together or are even fused.
 - **Interdigitations** : These are interfitting, finger like processes of the cell membranes of the adjacent cells.
 - **Intercellular Bridges** : These are minute projections that arise from adjacent cell membranes. They make contact with one another.



Showing microvilli, cilia, cell junctions and basement membrane



- **Gap Junctions** : Facilitate the cells to communicate with each other by connecting the cytoplasm of adjoining cells, for rapid transfer of ions, small molecules and sometimes big molecules.
- **Intermediate Junctions (= Zonula adherens)** : These usually occur just below tight junctions. The intercellular space at these places contains a clear, low electron density fluid. There is a dense plaque like structure on cytoplasmic side of each plasma membrane from which fine microfilaments of actin (protein) extend into the cytoplasm. There is no intercellular filaments between the adjacent cell membranes. There is an adhesive material at this point. They probably serve anchoring functions.
- **Desmosomes (=Macula adherens)** : Perform cementing to keep the neighbouring cells together. These are like zonula adherens but are thicker and stronger and are disc like junctions. They have intercellular protein. The plaque-like structures (= protein plate) are much thicker. The microfilaments which extend from microfilaments are called **tonofibrils**. Desmosomes serve anchoring function. **Hemidesmosomes** (single sided desmosomes) are similar to desmosomes, but the thickening of cell membrane is seen only on one side. Hemidesmosomes join epithelial cells to basal lamina (outer layer of basement membrane).

– **Specialised functional structures shown by Epithelial Cells : -**

Plasma membrane of free end get modified to form 3 types of functional structures.

Microvilli

- Minute protoplasmic process which are not non motile, non contractile.
- Help in absorption, secretion, excretion
- Increase surface more than 20 times.

Present in the wall of Intestine, Gall bladder, Proximal convoluted tubule etc.

Cilia or Kinocilia

- Long cylindrical protoplasmic process.
- Motile and contractile
- Movement of cilia is always in uniform direction.
- Originated from basal granule or kinetosome.
- Diameter of cilia is same from base to apex.
- In internal structure of cilia 9 + 2 arrangement of microtubules is present.
- They helps in conduction

e.g. – Fallopian tube.

- Trachea.
- Uterus.
- Uterus.
- Ependymal epithelium : (Inner lining of ventricles of brain & central canal of spinal cord. Function of cilia is to conduct substances in CSF.)

Steriocilia

- Long cytoplasmic process

- Non motile, non contractile
- Basal granule is absent
- Plasma membrane is thick & rigid.
- Base of stereocilia is broad & apical part is narrow so they are conical in shape.
- They increase surface area .

eg. Epididymis

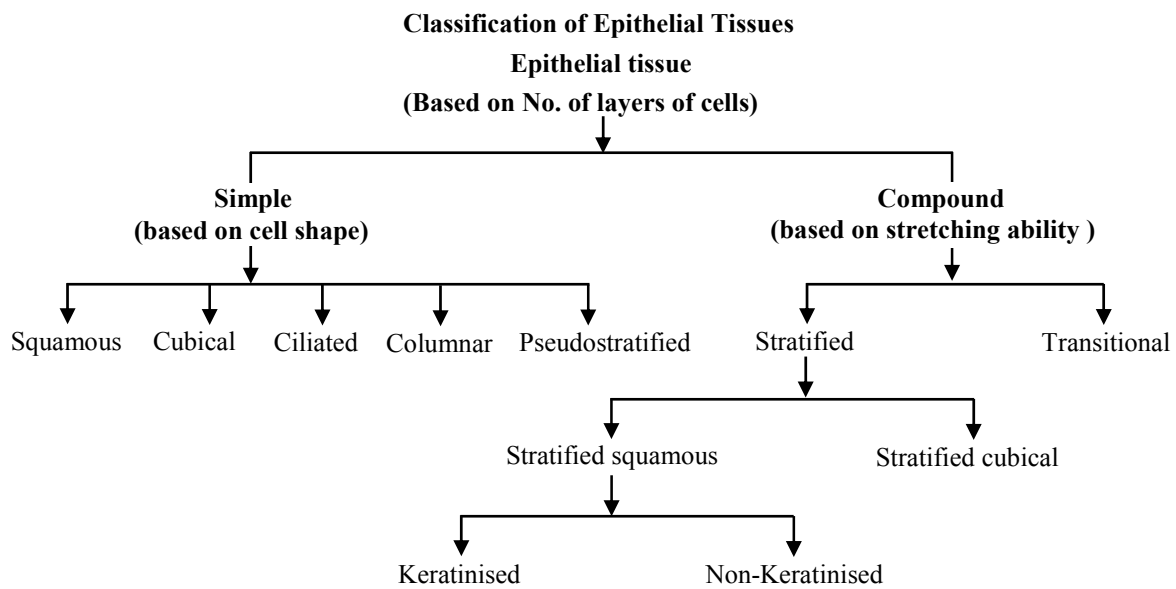
Vasadeferens

Origin of Epithelial Tissue

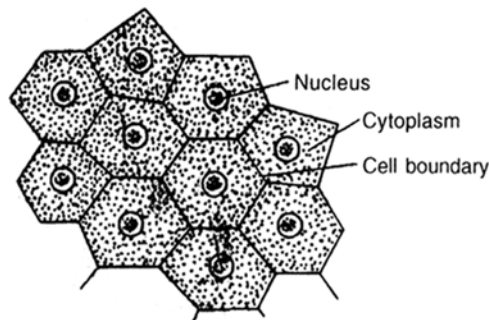
It is the only tissue which originated from all the three primordial germinal layers.

- eg. (i) Ectodermal – Epidermis (stratified squamous epithelium)
- (ii) Mesodermal – Mesothelium (simple squamous Epithelium)
- (iii) Endodermal – Endothelium (simple squamous Epithelium)

Types of Epithelial Tissue

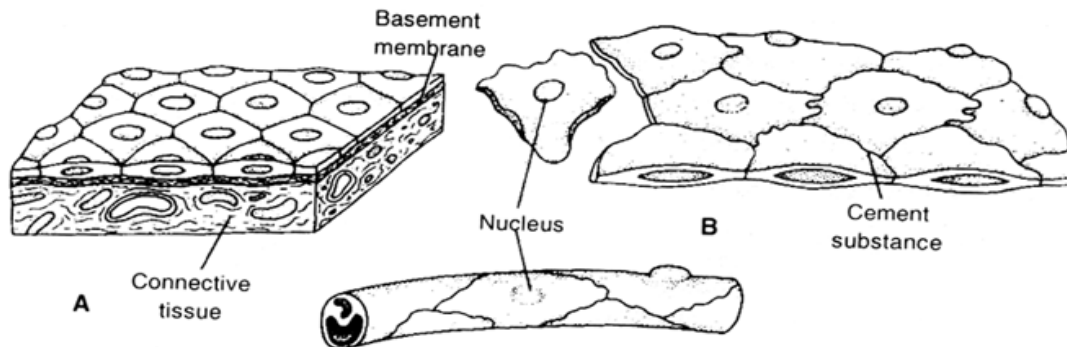


Simple Squamous Epithelium



(Simple squamous epithelium)

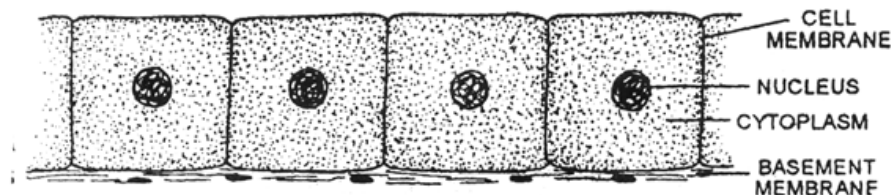
- Unilayered.
- Cells are flat or scale like in shape
- A flattened/rounded nucleus present.
- Cells are more in width and less in length so in vertical section they appear rectangular in shape.
- It is also called **pavement epithelium** due to its tile like appearance.
- Also called **Tesselated epithelium** due to its wavy appearance.
- This epithelium is associated with **filtration & diffusion**



- eg. – Bowman's capsule (Podocyte)
- Descending limb & thin part of ascending limb of loop of Henle.
 - Rete Testis
 - Alveoli of lungs (Pneumocytes)
 - Small bronchioles
 - Mesothelium – Covering of coelom is called as mesothelium. (Tesselated)
 - Visceral & Parietal peritoneum. Visceral and parietal pleura, Visceral and Parietal pericardium.
 - Endothelium – Inner lining of blood vessels and lymph vessels. (Tesselated)
 - Inner lining of heart wall (Tesselated).

Simple Cuboidal Epithelium

- Basement membrane is present.
- Cells are cube like in shape
- A rounded nucleus is present in the centre of cell.
- Cells are same in length & width so they appear square shaped in vertical section.



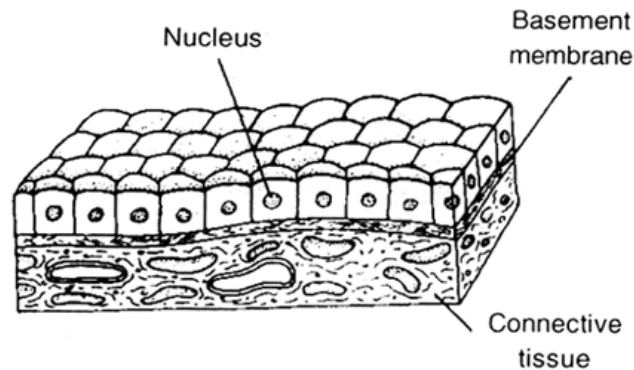
(Simple cuboidal epithelium)



- This epithelium helps in absorption, secretion & excretion.

It also form gametes in gonads.

Mostly cuboidal cells are found in glands.



- eg. - Vesicles of Thyroid gland
- Acini of Pancreas
 - Pancreatic duct
 - Secretory unit of sweat glands

Sweat glands are coiled tubular glands in structure.

Coiled part of this gland has secretory unit in the form of simple cuboidal epithelium is present while in secretory duct of this gland **stratified cuboidal epithelium** is present.

- **Secretory duct of salivary glands**
(secretory unit of salivary glands is composed is **stratified cuboidal epithelium.**)
- **Iris**
- **Choroid**
- **Ciliary body of eye**
- **Thick part of ascending limb of loop of henle**
- **DCT**
- In gonads this epithelium is also called as **Germinal epithelium** (testis & ovaries) where cuboidal cells divide to form egg & sperm.
- It is found in peripheral region of ovary & seminiferous tubules in Testis.

Modifications

Brush bordered cuboidal epithelium where microvilli are present on free and cuboidal cells
eg. - Found in PCT of nephron.

- Ciliated cuboidal epithelium** when cilia present on free end of cuboidal cells then
- Found in certain part of nephron and in collecting duct.

SIMPLE COLUMNAR EPITHELIUM

- Basement membrane is present.

- Cells are pillar or column like in shape.
- Elongated nucleus is present at the base of cell.
- It helps in absorption and secretion.

eg. **Bile Duct**

Liver

Modifications

Brush Bordered Columnar epithelium :

Microvilli are present at free end of epithelium.

e.g. Gall bladder

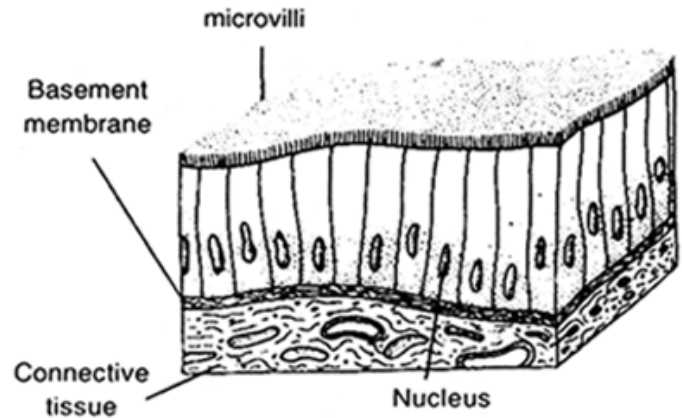
Gladndular columnar epithelium :

Unicellular mucous secreting **goblet cells** are also present in between columnar cells.

eg. Stomach

Colon

Rectum



Glandular Brush bordered columnar epithelium :

Microvilli present on free end of columnar cells & in between these cells goblet cells are also present.

e.g Duodenum

Ileum

Caecum.

Ciliated Columnar epithelium :

Cilia are present on free end of columnar cells.

Eg. Fallopian Tube

Ependymal epithelium

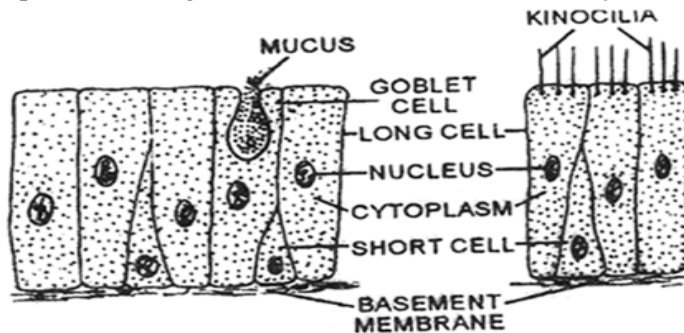
Steriociliated columnar epithelium : Steriocilia present on free end of columnar cells.

Eg. Epididymis

Vasa Deferens

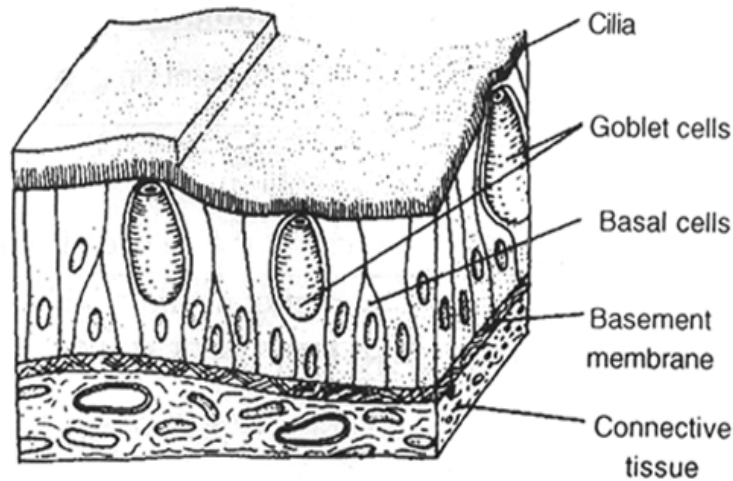
PSEUDOSTRATIFIED EPITHELIUM

- It appears bilayered as two types of cells are present i.e. Long cells Short cells.
- But all the cells are present on single basement membrane so its unilayered.



(Pseudostratified columnar & ciliated columnar)

- All these cells are pillar like in shape so it is also modification of columnar epithelium.
- In long cells, elongated nucleus is present at the base of cell & are ciliated Short cells have rounded nucleus present in the centre of cell, lack cilia and secrete mucus.



Modification

Pseudostratified Non-ciliated Epithelium eg, Parotid Salivary gland middle part of male urethra.

Pseudostratified ciliated glandular epithelium :

In this epithelium cillia are present at free end of long cells and goblet cells are also present in this epithelium.

eg. Trachea

Bronchi

Respiratory epithelium of nasal chambers.

Special Types of Epithelium

(a) Neuro sensory epithelium :

In between piller shaped supporting cells modified sensory cells are present. On the free end sensory hair is present. Base of these cells is attached with sensory nerve.

Eg. - Gustatory Epithelium - Cover taste bud of tongue and receive taste sensation.

- Olfactory epithelium - Schneidarian membrane receive smell sensation.

- Stato - acoustic - Lining of internal ear.

- In retina of eye receive optic sensation.

(b) Myoepithelium : Around mammary and sweat gland

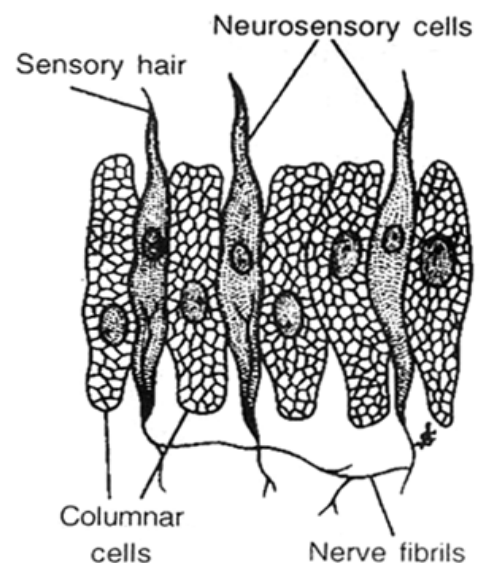
(c) Pigmented epithelium (Cuboidal) : In Retina of eye

COMPUND EPITHEIUM

(1) Transitional epithelium - Stretcheable.

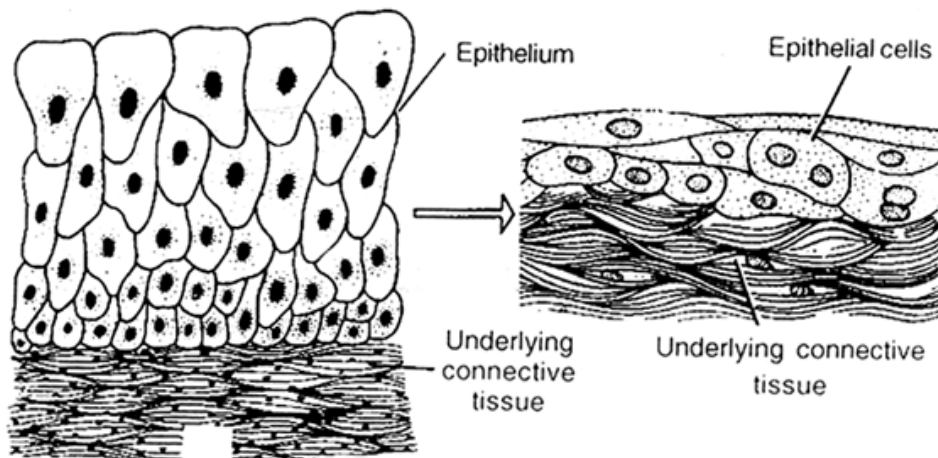
(also called Plastic epithelium)

(2) Stratified epithelium - Non-stretcheable.



TRANSITIONAL EPITHELIUM (UROTHELIUM)

- It is only tissue in which basement membrane is absent. So innermost layer directly rest upon underlying connective tissue.



- In this epithelium 4-6 layer of cells are present.
- Inner most layer of cells is composed of **cube like cells**.
- Middle 2-4 layers are composed of pear shaped or umbrella shaped cells.
- Outermost 1 or 2 layers are of oval shaped cells.
- These different shape of cells appears only in resting stage. When this tissue is stretched, all the cell become flattened.
- At outermost layer a thin cuticle is present which makes this tissue water proof.
- Cells are interconnected by interdigitation.

Eg. – Renal Pelvis

- Ureter
- Urinary Bladder
- Proximal part of male urethra.

STRATIFIED EPITHELIUM

- Stratified epithelium possess many layer of epithelial cells, the deepest layers is made up of cuboidal cells.

On the basis of shape of the cells of outermost layer it is of four types.

- (1) **Stratified squamous epithelium**
- (2) **Stratified cubical epithelium**
- (3) **Stratified columnar epithelium**
- (4) **Stratified ciliated columnar epithelium**

STRATIFIED SQUAMOUS EPITHELIUM

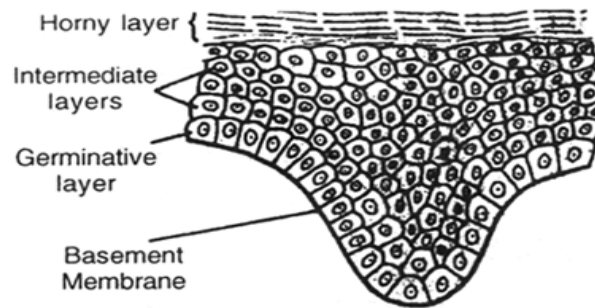
- Innermost layer of cells are of cuboidal or columnar shaped.
- These cells have high Mitotic index



- They divide to form layer of Stratified epithelium so this layer is called as **Germinativum** layer. Middle layers are made up of polygonal cells.
- These cells are interconnected with Desmosomes which provide rigidity or mechanical support.
- Cells of outermost layer are scale like flat cells.
On the basis of presence or absence of Keratin protein in the outer most cells this epithelium is of two types.

Keratinized Stratified squamous epithelium .

Hard water proof keratin protein is present in scaly cells and cells become non nucleated dead cells.



(Stratified squamous)

- eg. – Epidermis of skin
– Scale
– Horn
– Nails
– Feathers

Non Keratinized Stratified squamous epithelium . Keratin protein is absent. Cells are nucleated & Living.

- eg. Buccal cavity or oral cavity of mammals
Inner lining of cheeks
Inner lining of lips
Lining of hard palate.
Lining of Tonsils.
Lower part of soft palate.
Pharynx
Oesophagus
Anal canal
Lining of vagina
Cornea of eye

STRATIFIED CUBICAL EPITHELIUM

- Outermost layer of cells are cube like & cells are nucleated & living.
 - Middle layer – polygonal shaped cells.
- Eg. – Secretory duct of seat glands, mammary glands and sebaceous gland.
– Secretory unit of salivary glands, sebaceous gland.



- Female Urethra ; part of anal canal.
- Conjunctiva of eye.

STRATIFIED COLUMNAR EPITHELIUM

It consists of columnar cells in both superficial basal layers. Cells are nucleated. Cilia absent on free end.

- Eg. - Distal part of male urethra
- Epiglottis

Functional classification of epithelial tissue

Functionally epithelial tissues can be classified as follows :

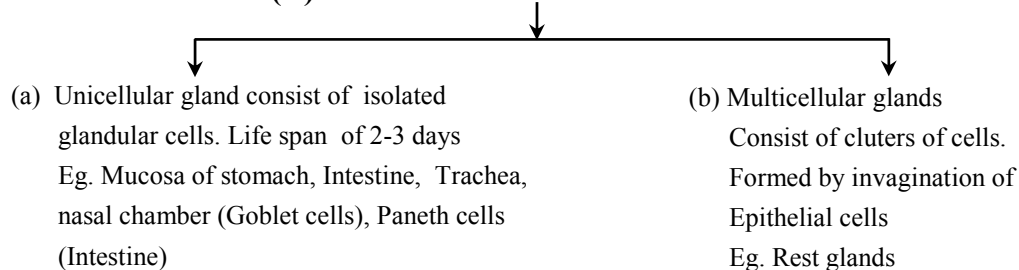
- Germinal epithelium** : It is present in testis and ovaries. Its cells produce **Sperms** and **Ova**.
- Pigmented epithelium** : It is present in retina of eye. It possess pigment which give colour to the retina.
- Sensory epithelium** : It is found in retina of eye, internal ear, nasal chamber and tongue. It perceives stimuli and conducts impulses.
- Glandular epithelium** : It is present in glands and secrete fluid (Secretion)
- Absorptive epithelium** : It is found in nephron of kidneys, stomach, intestine, It helps in absorption of food in stomach and intestine and liquid materials in nephron.

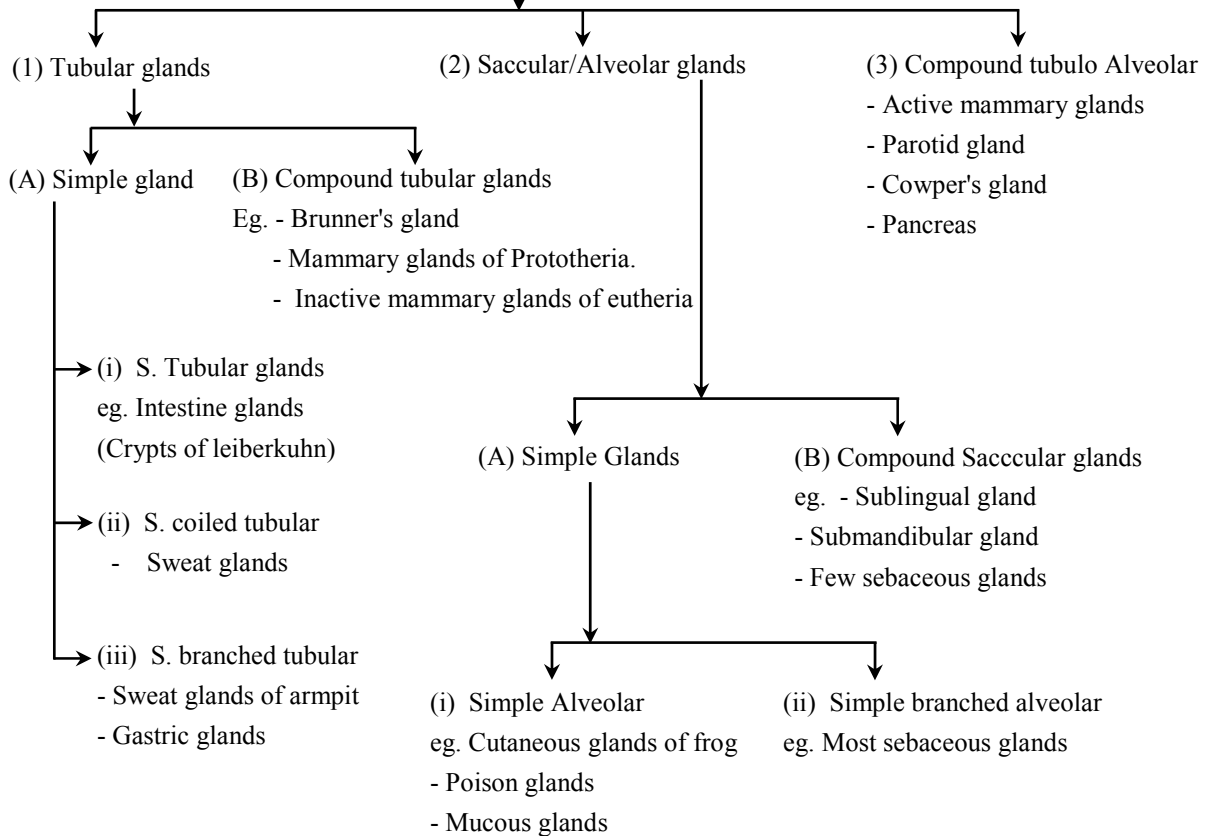
GLANDS OF EPITHELIUM ::

- A cell or group of cells which secrete chemical substances are called glands.
- All glands are composed of Epithelium tissue.
- Glands originate from all three germinal layers.
- The cells are generally columnar or cuboidal.

TYPES OF GLANDS

(A) On the basis of number of cells



**(B) On the basis of Shape of secretory units****(C) On the basis of presence of secretory duct glands are of 3 types**

- (a) **Endocrine glands** – Secretory duct absent
- (b) **Exocrine gland** – Secretory duct present.
- (c) **Heterocrine/mixed gland** – Both endocrine & exocrine parts are present.

(D) On the basis of nature of secretion – 3 types of glands are there.

Eccrine/Acrine/Merocrine gland – In these glands secretory cells secrete substances by simple diffusion (Exocytosis). No part of cytoplasm is destroyed in secretion.

Eg. Maximum sweat glands of humans, Paws of rabbit, Goblet cells, Salivary gland, Tear gland, Intestinal gland, Mucous gland.

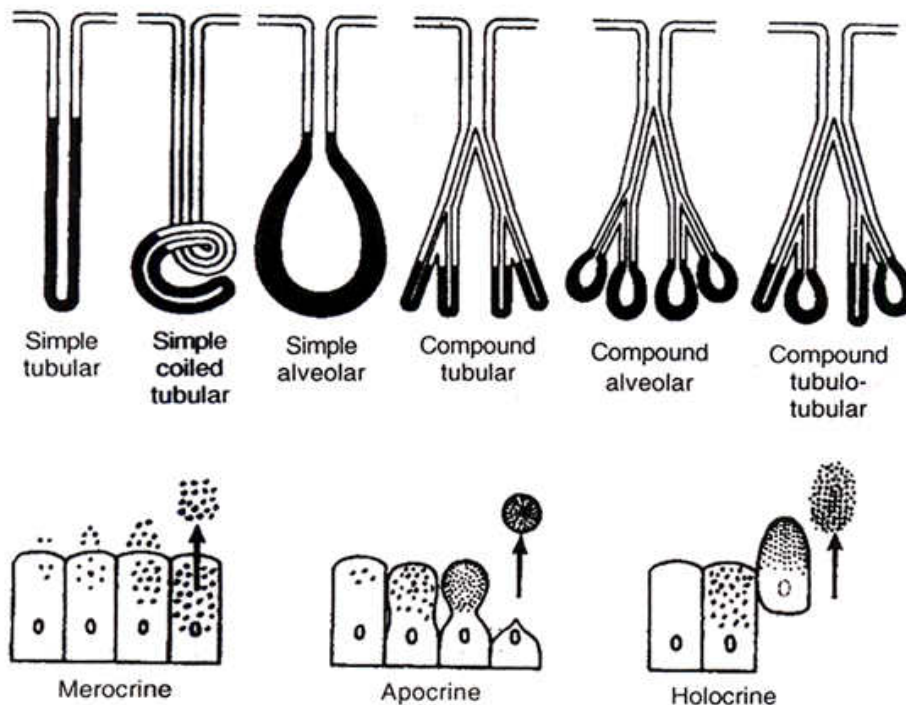
Apocrine gland – In this type of glands secretory products are collected in apical part of secretory cell. Apical portion is also shed along with secretory matter.

Secretory cells gain their lost part of cytoplasm by process of regeneration.

– Mammary glands.

Sweat gland of Arm pit, pubic region, skin around anus, lips, nipples etc.

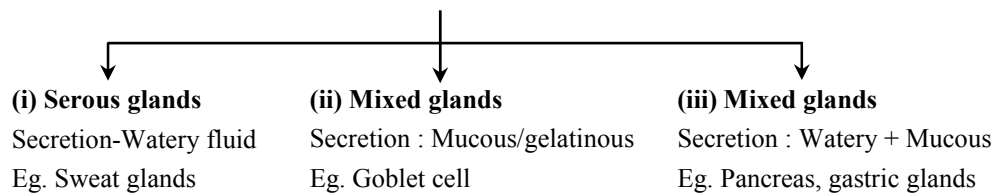
Largest sweat gland of body are found around nipples. – Areola mamme.



In Rabbit seat glands of this type are found on lips and skin around lips.

Holocrine glands – The production or secretion is shed with whole cell leading to its destruction. i.e
Example : Sebaceous, meibomian & Zeis gland.

(E) On the basis of secretory matter



CONNECTIVE TISSUE ::

- All connective Tissue in the body are developed from Mesoderm.
- O. Hartwig called them **Mesenchyme** because they originated from embryonic mesoderm.
- Only connective Tissue constitute **30%** of total body weight.
(Muscle – 50%, Epithelium – 10% Nervous – 10%)
- On the basis of **matrix** connective tissue is of 3 types
 1. **Connective Tissue Proper** – Matrix soft and fibrous
 2. **Connective Tissue Skeleton** – Dense and mineralized matrix. Due to deposition of minerals it becomes hard.
 3. **Connective tissue Vascular** – Liquid and fibres free matrix



CONNECTIVE TISSUE PROPER ::

Connective Tissue Proper is composed of three components

- (A) Different types of cells.
- (B) Fibres.
- (C) Matrix.

CELLS OF CONNECTIVE TISSUE PROPER

FIBROBLAST CELLS

- Largest cell of connective tissue proper.
 - Maximum in number.
 - Cell body and nucleus both are oval shaped.
 - Branched cytoplasmic process arise from these cells so they appear irregular in shape.
 - Rich in rough ER because main or primary function is to produce fibres. Fibres are composed of protein.
 - Chief matrix producing cells.
 - Old fibroblast cells (fibrocyte) are inactive cells.
 - These are also considered as undifferentiated cells of conn. Tissue because they can be modified into **Osteoblast & Chondrioblast** cells to produce bone & cartilage.
- Function :** (1) To produce fibres (2) To secrete matrix.

PLASMA CELL - CART WHEEL CELL

- Less in number.
 - Amoeboid in shape
 - Chromatin material is arranged like spokes in wheel so they are also called as **Cart wheel cells**.
 - According to research these cells are formed by the division of lymphocytes. So they are also called as **clone of lymphocytes**.
- Function :** Produce, Secrete & transport antibody.

MAST CELLS/MASTOCYTES

- Numerous, amoeboid and small in size.
- Structurally and functionally similar to basophils.
- 2-3 lobed S-shaped nucleus
- Cytoplasm contains basophilic granules which can be stained with basic dye Methylene Blue.
- It is important cell of connective tissue proper as they perform important functions.

(a) Histamine – Histamine is a protein, a vasodilator

- Increase permeability of blood capillaries.
- Take part in allergy and inflammatory reactions.

(b) Secotonin -

- Also called as 5-Hydroxy tryptamine
- It is a protein, a vasoconstrictor & decrease blood circulation but increases blood pressure.



- At the site of cut or injury serotonin decrease blood loss.

(c) **Heparin** - A mucopolysaccharide, a natural anti-coagulant, prevents clotting of blood in blood vessels by preventing the conversion of prothrombin into thrombin.

ADIPOSE CELLS/FAT CELLS

- Oval shaped stores fat.
- Fat is collected in the form of fat globule formed by the fusion of small oil droplets.
- On the basis of number of fat globules adipocytes are of two types.

Monolocular adipocytes/ White fat tissue-cell

- In these cells single large and central fat globule is present.
- nucleus & Cytoplasm is peripheral and Cytoplasm is less in amount.
- Due to compression of fat globule, nucleus become flattened in shape . These adipocytes form **White Fat**.

Multilocular adipocytes/Brown fat tissue cell

- In these cell 2-3 fat globules are distributed in the cytoplasm around nucleus
- Cytoplasm is more in quantity.
- Nucleus is rounded & found in the centre
- These adipocytes form **Brown Fat**.

MESENCHYMAL CELLS

- Less in numbers . Small sized with cytoplasmic process having irregular shape.
- Oval shaped nucleus
- These are undifferentiated cells of connective tissue because they can transform into any cell of connective Tissue proper. (Totipotent in nature)

Function : To form other cells of connective tissue.

MACROPHAGES/HISTEOCYTE/CLASMATOCYTES.

- It is 2nd largest in size and in number.
- Amoeboid in shape with bean or kidney shaped nucleus.
- Cytoplasm quantity is more agranular but due to presence of more number of lysosome it appears granular.
- Phagocytic in nature, destroy bacteria & viruses by phagocytosis. They arises by the fusion of monocytes
- Also called as **scavenger cells** of connective tissue because they destroy dead or damaged cells to clean connective tissue.

Macrophages are named differently in different organs.

Lung	-	Dust cells
Liver	-	Kupffer cells
Blood	-	Monocytes
Brain	-	Microglial cells
Thymus gland	-	Hessels granules
Spleen	-	Reticular cells



LYMPHOCYTES

- Less in number and small in size having amoeboid shape.
- A large nucleus is present cytoplasm is present as peripheral layer. Cytoplasm quantity is less.
- Produce, transport & secretes antibodies.
- They divide to form plasma cells of connective tissue proper.

FIBRES

Collagen fibres (White fibres)

- They are shining white fibres composed of collagen protein (Tropocollagen).
- It is present in maximum quantity in vertebrates, (only collagen fibres constituted one third part of connective tissue fibres in human beings.)
- They are wavy & tough fibres always arranged in bundle called fascia.
- On boiling they convert into gelatin.
- They can be digested by Pepsin enzyme.

Elastic fibres – (Yellow fibres)

- Precursor in colour and composed of elastin protein.
- They are branched fibres but always arranged singly. Branches of these form network.
- In these fibres maximum elasticity is present.
- They are highly resistant to chemicals.
- When boiled they do not dissolve.
- They can be digested by **trypsin** enzyme.

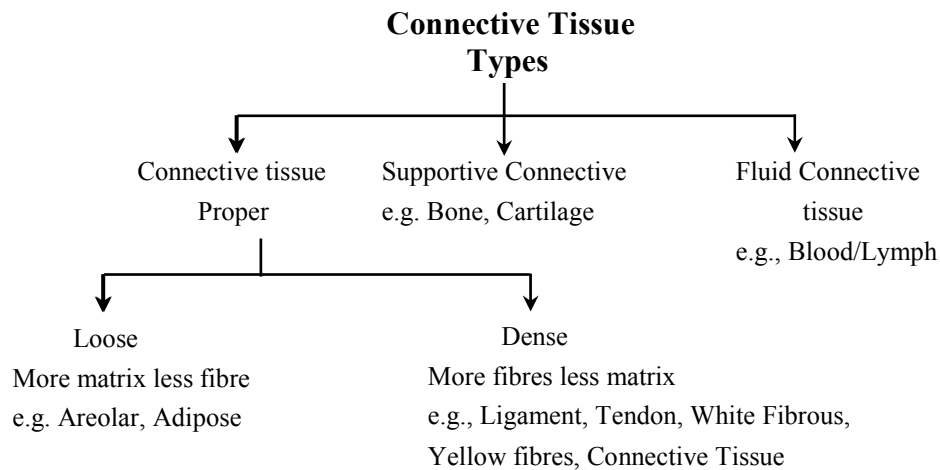
Reticular Fibres : -

- Precursor of Collagen fibres, delicate with no elasticity
- Also known as Arzyrophil fibre since they can be stained with silver salts.
- They are composed of reticulin protein highly branched fibres which always form dense network
- These are mainly distributed in lymphoid organs like spleen or lymph nodes

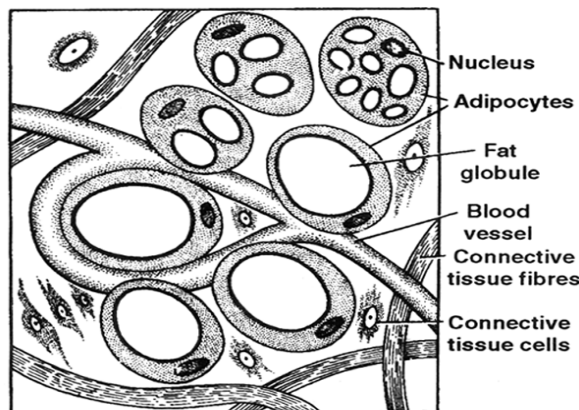
MATRIX

- Matrix is composed of Mucopolysaccharide which is present in the form of Hyaluronic acid.

TYPE OF CONNECTIVE TISSUE PROPER



Connective Tissue Proper



Adipose connective tissue

Loose Connective Tissue : It consists of cells scattered within an amorphous mass of proteins that forms a ground substance. The gelatinous material is strengthened by a loose scattering of protein fibres such as collagen, elastin, which makes tissue elastic and reticulin which supports the tissue by forming a collagenous meshwork.

AREOLAR CONNECTIVE TISSUE

- Also known **spongy** tissue.
- It is most widely distributed tissue in the body.
- In this tissue maximum intercellular space or substances/matrix is present.
- Due to irregular arrangement of bundle of collagen fibres many gaps are present. These spaces called

Areolae.

- In areolae other components of connective tissue are distributed like fibres, cell & matrix.
- Few elastic fibres are present but reticular fibres are completely absent.
- Mast cells, Macrophage & Fibroblast contain mone amount.



- It occurs beneath the epithelia of many visceral organs skin and in the walls of blood vessels.
- Fibroblast is the main cell.

Eg. Tela Subcutanea – A thin continuous layer which connect skin with underlying skeletal muscles (Pannicules carnosus). In mammals skin is tightly attached with muscles.

While in frog it is present in the form of septum so skin is loosely attached with muscles.

Endomysium – Around single muscles fibre.

Perimysium – Around bundle of muscle fibre.

Outside of seminiferous Tubules.

Medulla of ovary

Sub mucosa of trachea, Bronchi, Intestine

→ **The areolar tissue joins different tissues and forms the packing between them and helps to keep the organs in place and in normal shape.**

ADIPOSE CONNECTIVE. TISSUE

- Modification of Areolar connective tissue. But in areolae major component is adipocytes which store fats.
- Blood vascular system is also present in this tissue.
- If this tissue is treated with alcohol (organic solvent) Fat will be dissolved completely and adipocytes will become vacuolated.
- This tissue can be stained with sudan solution.
- On the basis of adipocytes 2 type of fats are found in animals.
 1. White fat
 2. Brown fat

White fat – It is composed of monolocular adipocytes in which single large fat globule & peripheral cytoplasm is present. Due to less amount of cytoplasm, Mitochondria are also less in number, so they produce less energy.

Eg. Panniculus adiposus – A thin continuous layer of white fat under the dermis of skin which is also called **hypodermis** of skin.

Panniculus adiposus is absent in rabbit. Fat collected in form of adipose connective tissue is a discontinuous layer.

Blubber – Thick layer of white fat found under dermis of skin. Found in whale, seal, elephants. Maximum thickness of this layer is found in Blue whale (80 cm)

Hump of camel

Tail of marino sheep

Yellow Bone marrow.

Brown fat – It is composed of multilocular adipocytes in which many fat globules are present. Cytoplasm is more in amount. Due to more number of mitochondria, it produces 20 times more heat than white fat. Brown colour of fat is due to Cytochrome Pigment.

- Cold resistance device in new born baby is due to presence of brown fat. It accounts for 5-6 percent of body wt.
- It cannot be substituted for food.

- In hibernating animals during hibernation they obtain energy from stored brown fat.
- When fat is oxidized it produce water & energy.

Dense Connective Tissue – Fibres and fibroblasts are compactly packed in the dense connective tissues. Orientation of fibres show a regular or irregular pattern and are called dense regular and dense irregular tissues.

In the dense regular connective tissues, the collagen fibres are present in rows between many parallel bundles of fibres e.g. tendons and ligaments.

Dense irregular connective tissue has fibroblasts and many fibres (mostly collagen) that are oriented in different directions. This tissue is present in the skin, in perimysium, perineurium and bones as periosteum.

WHITE FIBROUS CONNECTIVE TISSUE

- Bundle of collagen fibres are more in quantity & other components of connective tissue proper are less in
- quantity. It has great tensile strength
- Yellow fibres & reticular fibres are completely absent.
- Its presence at joints between skull bones makes them immovable.
- On the basis of arrangement of fibres and matrix this tissue occurs in two forms –

Cord

1. Bundle of collagen fibres & matrix are distributed in regular pattern (alternate pattern).
2. Fibroblast cells are arranged in a series. Mast cells are scattered in matrix.

eg. **Tendon** connects muscles & bones.

Strongest tendon of the body is **Tendocalcaneus Tendon**. This tendon connects Gastrocnemius muscles of shank with calcaneum bone of ankle.

Sheath – In this form there is no regular pattern of fibres & matrix. Cells and fibres are criss – crossed arranged.

eg. – **Pericardium**

- **Periosteum** – Outer covering of bone.
- **Perichondrium** – Outer covering of cartilage.
- **Perichondrium** – Covering of muscle.
- **Epimysium** – Around Kidney.
- **Renal capsule** – Covering of spleen.
- **Tunica Albugenia** – Covering of Testis.
- **Splenic capsule** – Covering of spleen.
- **Duramater** – Otermost covering of brain.
- **Cornea of eye**
- **Trachea**
- **Bronchi**
- **Oesophagus.**
- **Glison's capsule** – Around lobe of liver.

YELLOW FIBROUS CONNECTIVE TISSUE

- Yellow fibres are more in quantity but collagen fibres are also present.
- Reticular fibres are absent.
- On the basis of distribution of fibres & matrix they are of two types.

Cord : - Bundle of collagen fibres & matrix distributed in a regular pattern & in matrix yellow fibres form network.

eg. **Ligaments** – A structure which connects Bones.

- Strongest Ligament of body is **Ilio-femoral ligament** connects Ilium bone of pelvic girdle with femur bone of Hind limb.
- In quadrupeds like cow & buffalo strongest ligament is **ligamentum nuchea** present in the between two cervical vertebrae.

Sheath – Irregular distribution of fibres and matrix with Elastic fibre.

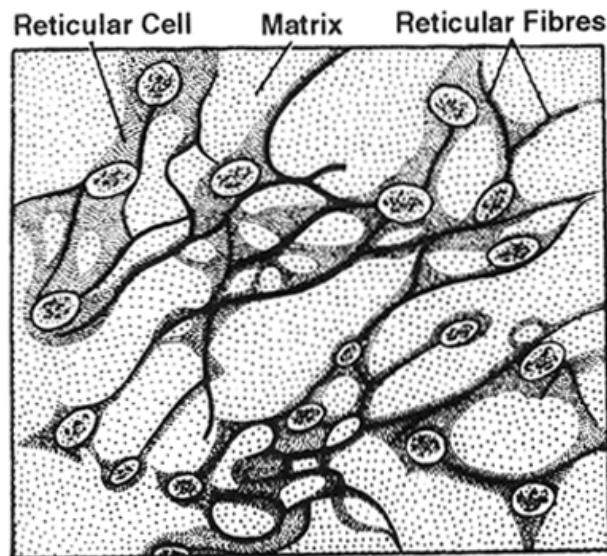
- eg. – **Wall of Alveoli of lungs**
- **Wall of small bronchioles**
 - **Wall of lymph vessels & Blood vessels**
 - **True vocal cords**

RETICULAR FIBROUS /LYMPHOID TISSUE

- It is mostly found in lymphoid organs.
- Matrix of this tissue is like lymph.
- Reticular fibres are more in amount & form dense network around star shaped reticular cells. (Phagocytic in function)
- Lymphocyte cells are also more in number.
- Provide support and strength and form the stroma (Frame work) of soft organs.

eg. – **Spleen**

- **Lymph nodes (Tonsils, Peyer's Patches).**
- **Cortex of ovary.**
- **Endosteum (covering of bone marrow cavity)**



Reticular tissue

- **Lamina Propria, Trachea, Bronchi , Intestine**



MUCOID CONNECTIVE TISSUE

Also called **Embryonic** Tissue because it is mainly found during embryonic life.

- Matrix is in abundance.
- Few collagen fibres & fibroblast cell may be present.
- Matrix is composed of jelly like material called **Wharton's Jelly**.

eg. – **Umbilical cord (connect Placenta with foetus)**

- **Vitreous humor – In vitreous body of eye.**
- **Comb of cock.**

PIGMENTED CONNECTIVE TISSUE

It is a modification of areolar connective tissue but in areolae pigmented cells are more in number known as **Chromatophores** with provide colouration.

Melanophore – Melanin – Black

Guanophore – Guanine – White

Xanthophore – Xanthophil – Yellow

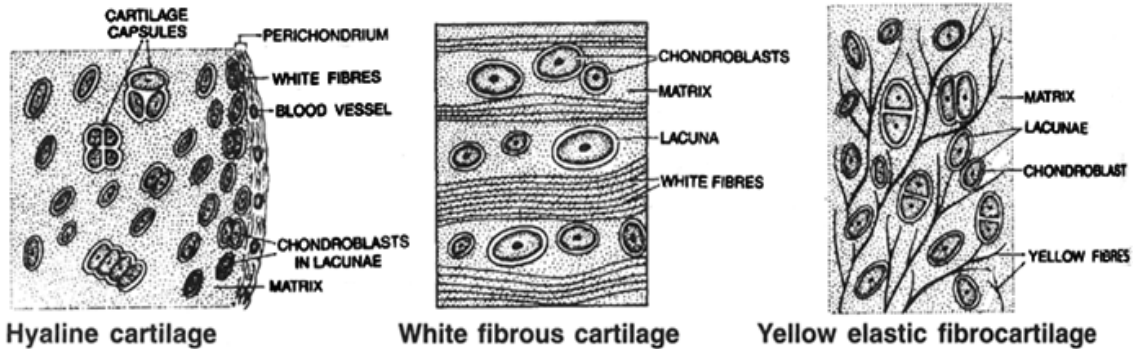
- eg. – **Dermis of frog skin**
- **Iris & choroids of eye.**

SUPPORTIVE CONNECTIVE TISSUE ::

- Matrix is dense mineralized. Due to deposition of minerals it becomes hard.
- Also known as **Skeletal Tissue** from skeleton of body.
- It is of 2 types
 1. Cartilage – Solid, semi-rigid, flexible conn. tissue.
 2. Bone – Solid, rigid conn. tissue.

CARTILAGE ::

- Outer most covering of cartilage is called **Perichondrium** which is composed of white fibres connective tissue.
- Cartilage producing cells are arranged on periphery known as **Chondrioblast**.
- These are active cell & divide to form chondriocytes, and synthesize the matrix of cartilage.
- Mature cells of cartilage are called **Chondriocytes**.
- They are found in vacuole like space in matrix called Lacuna. In which 2-3 Chondrocytes are present.
- **Chondrioclast** are cartilage destroying cells.
- Maxtrix of cartilage is called **Chondrin** composed of Chondromucoprotein having Chondroitin-6-sulphate and Mucopolysaccharide (Hyaluronic acid)
- Matrix of cartilage provides rigidity & elasticity to cartilage.
- Blood circulation is absent in the matrix of cartilage.



Type of Cartilage – There are following types of cartilage.

1. Hyaline Cartilage.
2. Fibrous Cartilage – (a) Elastic cartilage (b) white fibrous cartilage
3. Calcified Cartilage.

Hyaline cartilage

- Most of the part of embryonic skeleton is composed of this cartilage. Therefore, maximum bones of body are cartilaginous bones because they are developed from cartilage.
 - Outermost covering **Perichondrium** is present.
 - Matrix of this cartilage is **glass like** clear or hyaline matrix. Fibres are completely absent in the matrix of this cartilage. Only few collagen fibres may be present.
 - Colour of matrix is bluish and it is translucent.
- eg. – **Nasal septum.**
- **'C' shaped rings of trachea and Bronchi.** (Incomplete in dorsal surface)
 - **Sternal part of ribs.** (Costal cartilage)
 - **Larynx : Thyroid, Cricoid, Arytenoid.** Maximum part of Larynx is composed of hyaline cartilage.
 - **Articular cartilage** – At the junction of two long bones on articular surface. At the end of long bone periosteum is absent and Hyaline cartilage is present known as Articular cartilage.

Fibrous cartilage

Elastic cartilage

- Perichondrium is present.
- In the matrix yellow fibres form network so it is highly flexible cartilage of body
- Colour of matrix is pale yellow.

Eg. – **Tip of Nose**

- **Ear Pinna**
- **Epiglottis**
- **Larynx** – Cartilage of santorini of larynx
- **Wall of Eustachian tube**

White fibrous cartilage

- Perichondrium is absent because complete white fibrous connective tissue is converted into cartilage.



- In matrix bundle of collagen fibres are more in quantity so it is **strongest cartilage**.

Eg. **Pubic symphysis**

Pubis bone (Half part of pelvic girdle osinnomineta) are interconnected by pubic symphysis.

Intervertebral disc

A pad of cushion like structure which absorb mechanical shock and jerks and protect vertebral column.

Central part of this disc is soft called as Nucleus pulposus. (remnant of embryonic Notochord)

Slight elongation of body after death or in sleeping posture is due to relaxation of this disc.

Calcified cartilage

- It is modified hyaline cartilage but due to deposition of calcium salts its matrix becomes hard like bones.

- It is **hardest cartilage** of the body

- Ca salt deposits in the form of Hydroxy apatite $\text{Ca}_{10}(\text{PO}_4)_6(\text{OH})_2$.

Eg. - Pubis of frog's pelvic girdle.

- Supra scapula of pectoral girdle

- Head of Femur & Humerus

BONE ::

- Study of Bone – **Osteology**

- Process of bone formation – **Ossification**

- Hardest Tissue – Bones

- (Softest Tissue – Blood.)

- Hardest substance – Enamel. (It is not a group of cell but it is formed by the secretion of ameloblast cells of teeth.)

- Outermost covering of bone is **Periosteum** composed of white fibrous connective tissue.

- Bone producing cell called **Osteoblast**. They divide to form **Osteocyte** & synthesize organic part of matrix.

- Mature cell of bone is called **Osteocyte** which is found in Lacuna. Only one osteocyte is found in lacuna.

- Bone destroying cells are **Osteoclast** cells.

Matrix

It consist of two parts.

Inorganic Part – 65 – 68%

$\text{Ca}_3(\text{PO}_4)_2$ – 80% max. rest 20% CaCO_3 , $\text{Mg}_3(\text{PO}_4)_2$, Flourides.

Organic part – 32-35% Ossein in which bundle of collagen fibres suspended in sulphated mucopolysaccharide.

Sharpey's fibre – extra bundle of collagen fibres which are present in the outermost layer of matrix called Sharpey fibres. They are also found in the cement of teeth which provide extra mechanical support to bone & teeth.

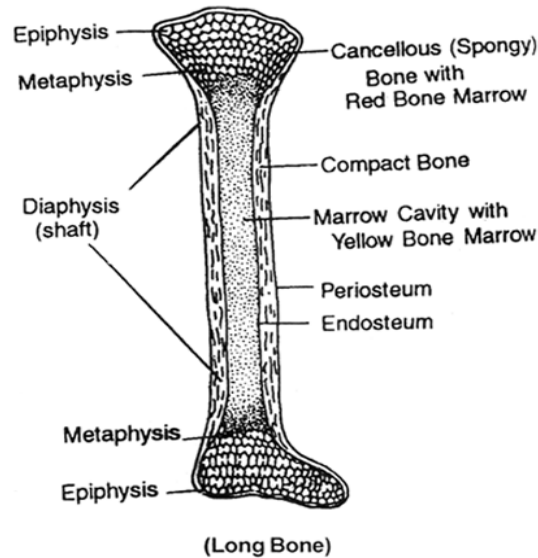
Structure of long bone :

Long bone has three region

Epiphysis

Diaphysis

Metaphysis



Epiphysis

- Ends of long bone is called **Epiphysis**. This part is composed of spongy bone. If this part is present at the joint then on articular surface **Periosteum** is absent & Articular cartilage (Hyaline cartilage) is present.
- Cavity is present in the form of **Trabeculae** filled with red bone marrow.
- It is composed of myeloid Tissue which produce blood corpuscles so epiphysis act as a **Haemopoietic** organ.

Diaphysis

- Middle part of shaft of long bone is diaphysis which is composed of **compact bone**.
- In this region hollow cavity is present called bone marrow cavity filled with yellow bone marrow composed of white fat. Function is storage of fat.
- If required in anaemic condition YBM is replaced by RBM.
- At the time of birth RBM is 70 ml while in adult it is 4000 ml.

Metaphysis

- It form little part between epiphysis & Diaphysis.
- In this region **epiphyseal plate** is present which is made up of osteoblast cells. They divide to form osteocyte and also synthesize matrix of bone, so epiphyseal plate is responsible for elongation of bone.
- After complete development of long bone this plate is destroyed. So a complete developed bone shows 2 regions while in a developing bone 3 regions are found.

Special points :

Spongy Bones

- Haversian system is absent. Marrow cavity is present in the form of Trabeculae filled with RBM. So all spongy bones of body are haemopoietic
- Eg. Ribs, Pubis, Sternum, Vertebrae, Clavicle, End of long Bones, Scapula



Compact Bone

Haversian system is present.

Eg. Diaphysis of long bone.

Diploic/Heterotypic

– Middle part of bone is composed of spongy bone, in which Trabeculae is filled with RBM. This bone is covered by compact bone on upper & lower surface.

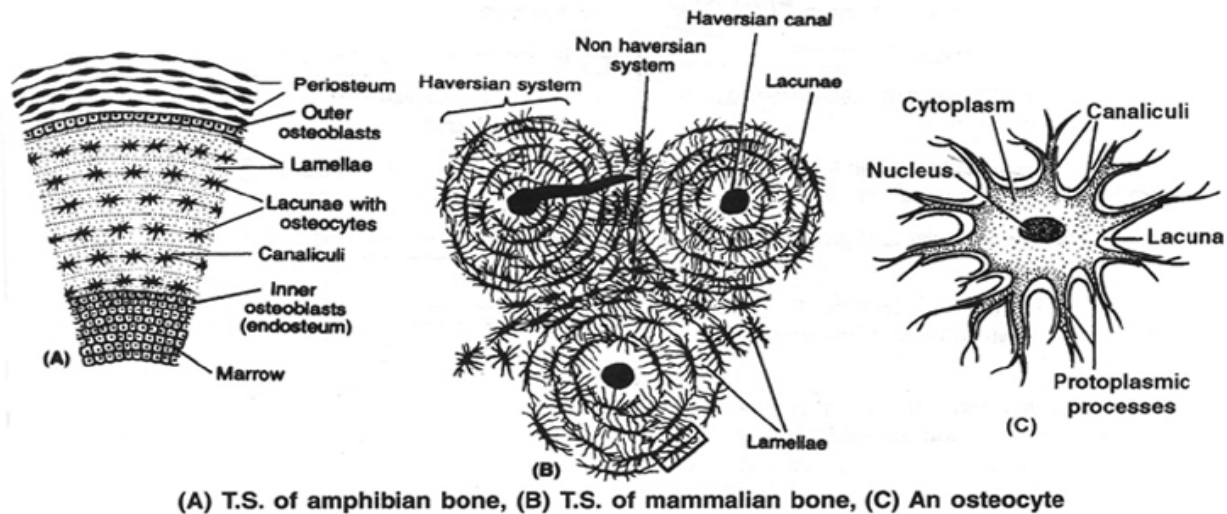
Eg. All flat bones of skull.

Pneumatic Bone

– In the matrix air filled spaces are present so bone become light in weight.

Eg. Bones of birds.

INTERNAL STRUCTURE OF MAMMAL BONE ::



(A) T.S. of amphibian bone, (B) T.S. of mammalian bone, (C) An osteocyte

It has following major structures.

- | | |
|---------------|-----------------------|
| 1. Periosteum | 2. Matrix |
| 3. Endosteum | 4. Bone marrow cavity |

PERIOSTEUM

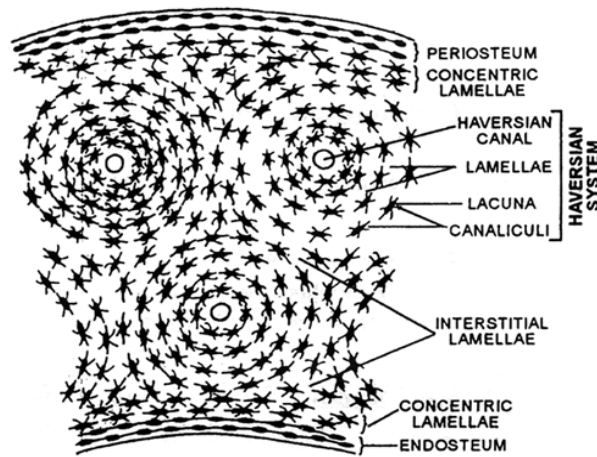
- Outermost covering consists of two layers.
- Outer layer consist of WFCT in which blood circulation is present.
- Inner layer – consists of single layer of osteoblast cells. These cells are cube like in shape in which oval shaped nucleus & basophilic granules are present in cytoplasm.
- They divide to form osteocyte and secrete layer of matrix.

Matrix

It is composed of inorganic & organic compounds.

– In the matrix of bone 2 types of canals are present.

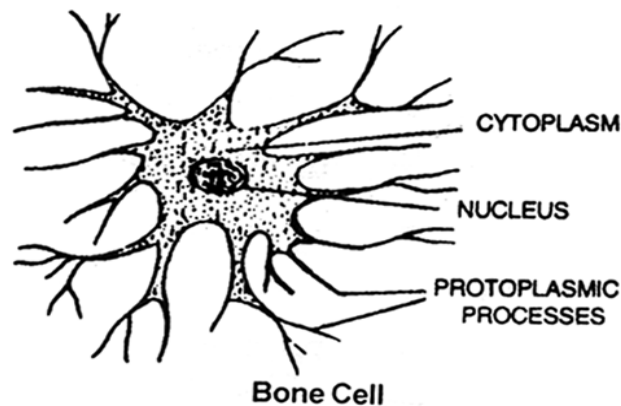
1. Haversian canal
2. Volkmann's canal



(T.S. of Mammalian long bone)

Haversian canals are central Longitudinal canals which are arranged parallel to long axis of bone. In this canals 1 or 2 blood capillaries and nerve fibres are present.

- Volkman canals are transverse/horizontal or oblique canals.
- Haversian canals are interconnected by means of volkmann's canal.
- Matrix of bone is synthesized in the form of layer called **Lamellae**. On the basis of arrangement 3 types of lamellae are present in the matrix.
 1. Haversian lamellae
 2. Interstitial lamellae
 3. Circumferential lamellae.
- Haversian lamellae are Concentric layers of matrix which are present around Haversian Canal.
- Between these lamellae layer of Osteocyte cells are also present.
- Haversian canal, Haversian lamellae & Osteocyte form **Haversian** system or **Osteon**.



Bone Cell

- Presence of Haversian system is a typical feature of **mammalian** compact bones.
- Osteocyte are present in the lacuna. Each Osteocyte is inter connected with adjacent Osteocyte by their cytoplasmic process.
- Cytoplasmic process of Osteocyte are present in the canals of lacuna called as **canaliculi**.
- Interstitial lamellae are present in the space between 2 haversian systems



Circumferential lamellae are of 2 types.

1. Outer circumferential lamellae :
 - These are present around all Haversian system.
 - These are peripheral layers of matrix.
2. Inner circumferential lamellae
 - Present around bone marrow cavity.

ENDOSTEUM

Endosteum consists of 2 layers.

- (a) Towards bone marrow cavity lined with layer of reticular fibrous connective tissue.
- (b) Towards matrix of bone lined with layer of Osteoblast cell. They divide to form osteocyte & synthesize matrix. So growth of bone is bidirectional (Periphery and central region). While Growth of cartilage is unidirectional.

BONE MARROW CAVITY

- In the central region hollow cavity is present which is filled with YBM. It is composed of white fat & its function is collection of fats or storage of fats.

TYPE OF BONES

On the basis of development or location of ossification bones are four types.

Cartilagenous bones/Replacing /Endochondral bone

- These bones are developed from cartilage or they are formed by the ossification of cartilage.
 - In the formation of these bones 2 types of cells are required.
 1. **Chondrioclast** – Which reabsorb cartilaginous matter.
 2. **Osteoblast** – Which deposit bony matter into cartilage so cartilage is replaced by bone. Hence these bones are also called as replacing bones.
- Eg. Maximum bones of our body like limb bones (Fore & Hind), Ribs ; vertebrae
Girdle bones except clavicle.

Membranous bones/Dermal bones/Investing bones

- These bones are developed from the connective tissue of dermis or formed by ossification in the connective tissue of dermis.

Eg. **Sternum, Nasal Bone, Clavicle, Vomer Bone, Skull bones.**

Flat bones of skull – Parietal Bone, Frontal, Larymal, Temporal

Bones of upper Jaw – Maxilla, Palatine

Bones of lower Jaw – Mandible (Human)/Dentary (other mammals)

Sesamoid Bones

- These bones are developed by the ossification of tendons at the joints.
- Eg. Pisiform (wrist bone) of man and rabbit. (One out of 8 carpals in man and 1 out of 9 carpals in Rabbit).
- Patella (knee bone) Largest sesamoid bone. (Patella and two fabillae in rabbit)
 - Fibulla (of Tibia – Fibulla)

Visceral Bones

– If ossification take place in the visceral organs then visceral bones are formed. These are rare bones, found in few animals. In rabbit & man these bones are absent.

- Eg. **Os Cardis** : Present in inter ventricular septum of Deer's heart
- Os Palpebrae** : In the eyelid of crocodile
- Os Penis (Baculum)** : In the Penis of rodents, rat, shrew, Bat, Whale, Tiger.
- Os rostralis** : In the snout of pig.
- Os falciparum** : Palm of mole

Table : Difference between a Dried bone and a Decalcified bone

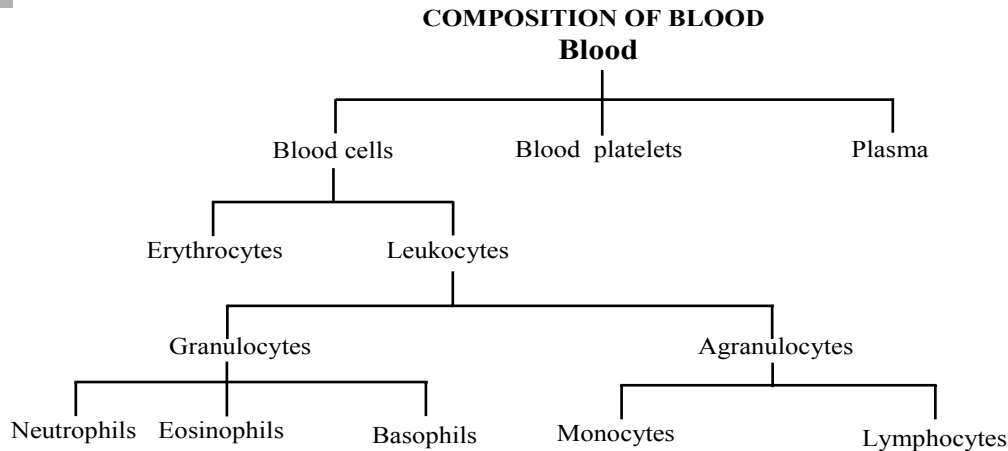
Dried bone	Decalcified bone
(i) It is a bone that has been dried by subjecting to a high temperature	(i) It is a bone that has been treated with dilution HCl.
(ii) It does not have the bone marrow. Bone marrow cavity is empty.	(ii) It has the bone marrow.
(iii) It contains mineral matter.	(iii) It contains only the organic matter.
(iv) Living structures are absent.	(iv) Living structures are present.

FLUID CONNECTIVE TISSUE ::

There are two types of Fluid connective tissue :

- (1) Blood (2) Lymph
- Matrix is liquid & fibre free

BLOOD ::



- Study of Blood – **Haematology**
- Process of blood formation **Haemopoiesis**.
- Colour – Red
- PH – 7.4 (Slightly alkaline)
- By weight – 7 to 8% of body weight
- By volume – 5 – 6 litres in male and 4-5 litres in female.



- Blood is a false connective tissue because
 - a. Cells of blood have no power of division.
 - b. Fibres are completely absent in blood.
 - c. Matrix of blood is produced and synthesized by liver and lymphoid organs.

Composition of Blood

Liquid Part – Matrix – Plasma 55%

Solid Part – Blood corpuscles – 45% (RBC, WBC & Platelets) [Formed Elements]

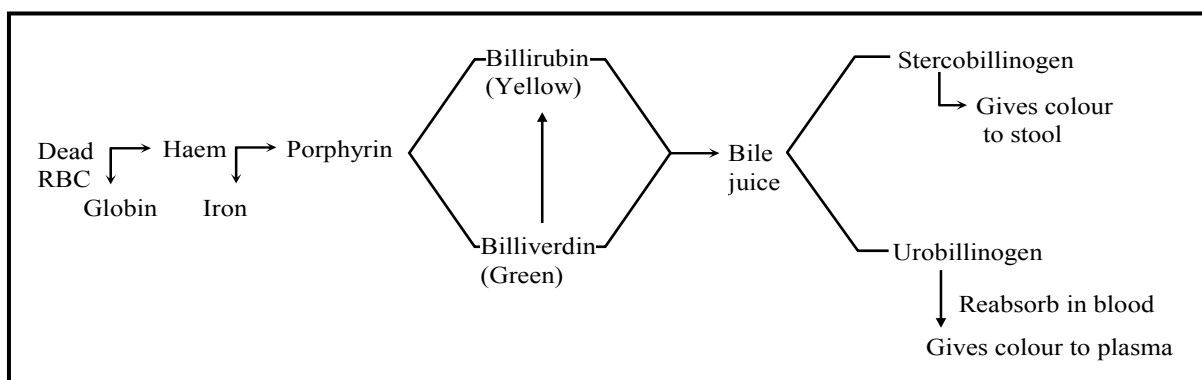
Packed cell volume – (PVC)% volume or Total number of blood corpuscles is blood.

Haematocrit Volume : - % volume or only number of RBC in blood.

PVC \approx HV because 99% of Packed cell volume is completed by RBC & in rest 1% WBC & Platelets are present.

PLASMA ::

- Matrix of blood is called Plasma.
- It is pale yellow in colour due to Urobilinogen. (Bilirubin)



Composition of plasma

Water : 90% - 92%

Solid part : 8 - 10%

In which inorganic and organic compounds are present.

Inorganic part of plasma - 0.9% in which -

- 1. Ions** – Na^+ , K^+ , Ca^{++}
 Cl^- , HCO_3^+ , SO_4^{--} , PO_4^{---}
 Cl^- , $> \text{Na}^+$
- 2. Salts** – NaCl , KCl , NaHCO_3 , KHCO_3
Maximum : NaCl (also called as common salt.)
- 3. Gases** – O_2 , CO_2 , N_2
Each 100 ml of plasma contains 0.29% O_2 , 0.5% N_2 , 5% CO_2
Present in dissolved form

**Organic Part of Plasma – 7% - 9%****Proteins**

6 – 7% Maximum

Albumin → 4% (Max.)

- Produced and synthesized by liver
- Responsible to maintain BCOP (28 – 32 mm Hg.)

Globulin : - 1.5% – 2.5 %

- Ratio of Albumin & Globulin is 2 : 1.
- Produce and secreted by liver and Lymphoid organs.
- Transport or carry substance in body.
- Destory bacteria virus & toxic substances.
- In blood 3 types of Globulins are present.

(i) **α-Globulin** – Produced by liver.
Eg. Ceruloplasmin – Cu carrying protein.

(ii) **β-Globulin** – Produced by liver
Eg. Transferin – Fe carrying protein.

(iii) **γ-Globulin** – Produced by Lymphoid organs

Present in the form of antibodies which destroy Bacteria, Virus & Toxic substance. Also called

Immunoglobulins .These are of 5 types. (Ig, G, IgA, IgM, IgD, IgE)**Prothrmbin** – 0.3% Produced by liver**Fibrinogen** – 0.3% Prodcued by liver

- Largest plasma protein .
- Help in blood clotting.

Digested Nutrients

Amino acid

Glucose

(Blood Glucose level – 80-100 mg %)

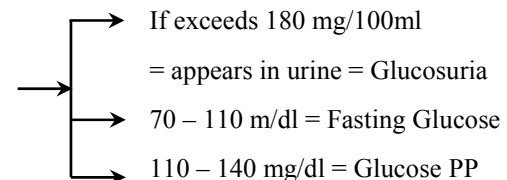
Fatty acid

Glycerole

Cholesterole

(Blood Cholesterol level - 80–180 mg/100ml)

vitamins

**Waste Products**

Urea

Uric acid

Creatine

Creatinine



Normal blood urea level 17-30 mg%

If blood urea becomes more than 40 mg this condition is called **Uremia** in which R.B.C. become irregular in shape called burr cell which are destroyed in spleen so uremia is a type of anaemia.

Anticoagulant

- Heparin-A Mucopolysacchride which prevent clotting of blood in blood vesels.

Defence compounds

1. **Lysozyme** : A protein which act as an enzyme which dissolve cell wall of the Bacteria & destroy them.
2. **Properdin** : Large protein molecules which destroy toxins synthesize by Bacteria or Virues so act as anti-toxin

Hormones

- Secreted by endocrine glands which are transported by blood plasma.

BLOOD CORPUSCLES ::

Erthrocytes (Red blood Corpuscles)

- Mammalian RBC's are Biconcave, circular & non nucleated.
- At the time of origin nucleus is present in the RBC but it degenerates during maturation process.
- Biconcave shape of RBC increase surface area.
- Due to absence of nucleus & presence of biconcave shape more Haemoglobin can be filled in RBC.

Exception :- Camel & Lama are mammals with bioconvex, oval shaped & nucleated RBC.

- In RBC Endoplasmic Reticulum is absent so endoskeleton is composed of structural protein, fats and Cholesterol present in the form of network called **stromatin** which is a spongy cytoskeleton.
- Plasma Membrane of RBC is called **Donnan's membrane**. It is highly permeable to some ions like Cl & HCO₃ ions and impermeable to Na⁺ & K⁺ inos. It is called Donnan's phenomenon.
- Due to presence of stromatin spongy cytoskeleton & flexible Plasma Membrane RBC (7. 5μ) can pass through less diameter blood capillaries (5μ)
- In RBC higher cell organelles like Mitochondria & Golgi complex is absent.
- Due to absence of Mitochondria anaerobic respiration takes place in RBC.
- In RBC enzyme of glycolysis process are present, while enzyme of Kreb's cycle are absent.
- In RBC carbonic anhydrase enzymes is present which increases rate of formation & dissociation of carbonic acid by 5000 times. (Fastest catalyst (with zinc))
- Antigen of blood group is present on the surface of RBC.
- If Rh Antigen is present then it is also found on the surface of RBC.
- Single RBC is pale yellow in colour while group of RBC appear red in colour.
- In RBC. red coloured respiratory pigment **Haemoglobin** is present.



- In each 26.5 crores molecules of Hb are present
- Molecular weight of each molecule of haemoglobin 67,200.
- In composition of RBC 60% H₂O & 40% solid part is present. Only Hb. Constitutes 36% of total weight of RBC and 90% on of dry weight.

Haemoglobin

It is composed of two components

1. Heam - 5% Lipid part
2. Globin - 95% Protein part

Heam (Iron and Porphyrin)

Iron Present in the form of Fe⁺²

While in muscles myoglobin is present where iron is present in the form of Fe⁺³

- Porphyrin is composed of **Acetic** acid and Glycine amino acid.
- Each molecule of Hb carries 4 molecules of O₂
- 1 gm Hb carries 1.34 ml O₂
- 100 ml blood contain 15 gm Hb
- 100 ml blood transport 20 ml O₂

Globin: Each molecule of globin protein is composed of 4 polypeptide chains. Polypeptide chains are of 4 types.

1. α polypeptide chain having 141 Amino Acids
2. β polypeptide chain having 146 Amino Acids
3. γ polypeptide chain having 146 Amino Acids
4. δ polypeptide chain having 146 Amino Acids

On the basis of these polypeptide chains 3 type of Hb are formed in human

- Hb A (Adult Hb) - $2\alpha + 2\beta$
- Hb A₂ (Adult-2) - $2\alpha + 2\delta$
- HbF (Foetal Hb) - $2\alpha + 2\gamma$

(Oxygen binding capacity of foetal Hb is more than adult Hb)

Size of RBC

- Human - 7.5 μ
- Rabbit - 6.9 μ
- Frog - 35 μ

- Largest RBC- Amphiuma 75-80 μ (Class Amphibia)
- Smallest RBC-Musk Deer 2.5 μ . (Class Mammalia)
- Largest RBC among all mammals in Elephant 9-11 μ

- Change in the size of RBC is called as **Anisocytosis**
- Due to Vit. B₁₂ deficiency RBC become larger in size called as **Macrocytes**. These are immature RBC which are destroyed in spleen. In these RBCs amount of haemoglobin is normal.
- Due to Fe deficiency RBC become smaller in size called as **Microcytes**. They are also destroyed in spleen. In these RBCs amount of haemoglobin is less.

Shape of RBC –

- Biconcave
- Change in the shape of RBC is called as **Poikilcoytosis**.
- Uremia-RBC become irregular in shape.
- Sickle cell anaemia-RBC become sickle shaped.
- If RBC is kept in Hypertonic solution it will shrink (crenation).
- In Hypotonic solution it will burst.
- 0.8-1% NaCl solution is isotonic for RBC. (0.9% of NaCl)
- 80-100 mg% of glucose is also isotonic.

Life span of RBC

Human	–	120 days
New Born Baby	–	100 days
Rabbit	–	80 days
Frog	–	100 days

Avg. life span of RBC in all mammals 120-127 days.

Radioactive chrominum method is used to estimate life span of RBC

RBC count

Number of RBC in per cubic mm of blood is called RB count.

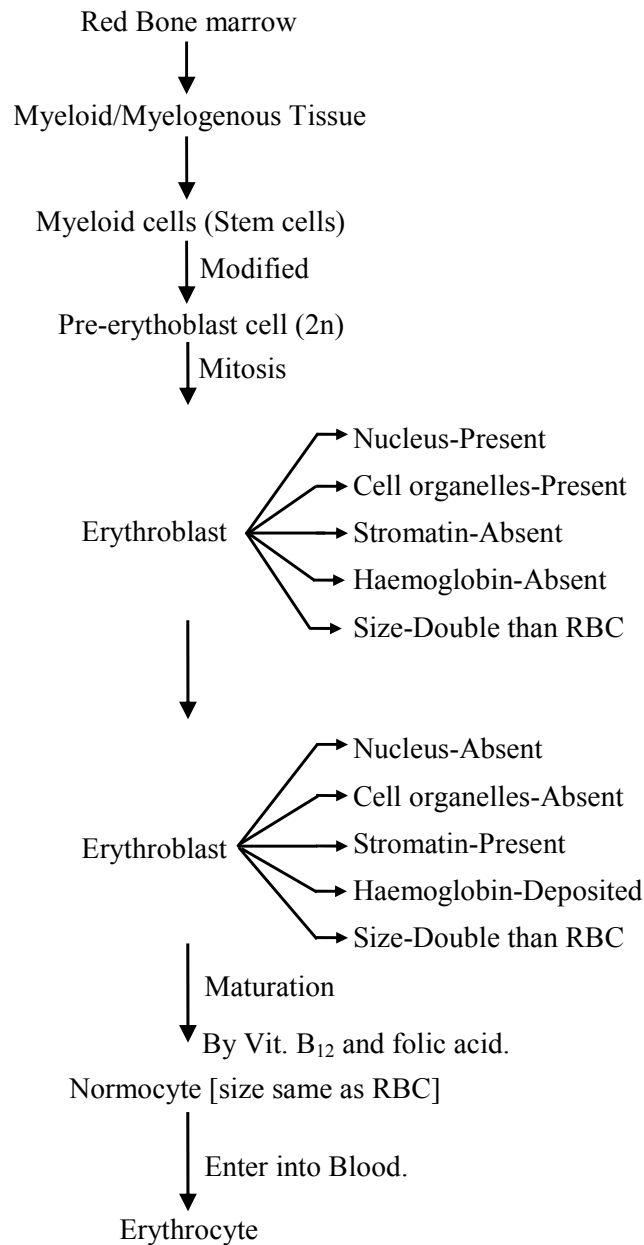
Human (Male)	5.5 million	→	15.5 ± 2.5 g/dl
Human (Female)	4.5 million		14.0 ± 2.5 g/dl
Newly born baby	6.8 million	└─┬─┘	16.5 ± 3.0 g/dl
Rabbit	7 million		
Frog	0.4 million		

- Increase in the RBC count condition is called **polycythemia**. This condition occurs at hill station.
 - Decrease in RBC count condition is called **Anaemia**.
1. **Macrocytic Normochromic anaemia** – Due to Vit. B₁₂ deficiency macrocytes are formed which are destroyed in spleen. In Macrocytes % of Hb is normal.
 2. **Microcytic/Hypochromic anaemia** – Due to Fe deficiency microcytes are formed.
 3. **Normocytic/Normochromic Anaemia** – Excess blood loss.



Formation of RBC

- Process of formation of RBC is called **Erythropoiesis**.
- Organs which produce RBC's called **Erythropoietic organs**.
- Hormone which stimulate Erythropoiesis is called **Erythropoietin** synthesized by Kidney.
- 1st RBC is produced by yolk sac.
- During embryonic life RBC are produced by Liver, Spleen, Placenta, Thymus gland.
- In adult stage RBC is produced by RBM which filled in Trabeculae of spongy bones.
- Kidney is an erythropoietic organ in frog.

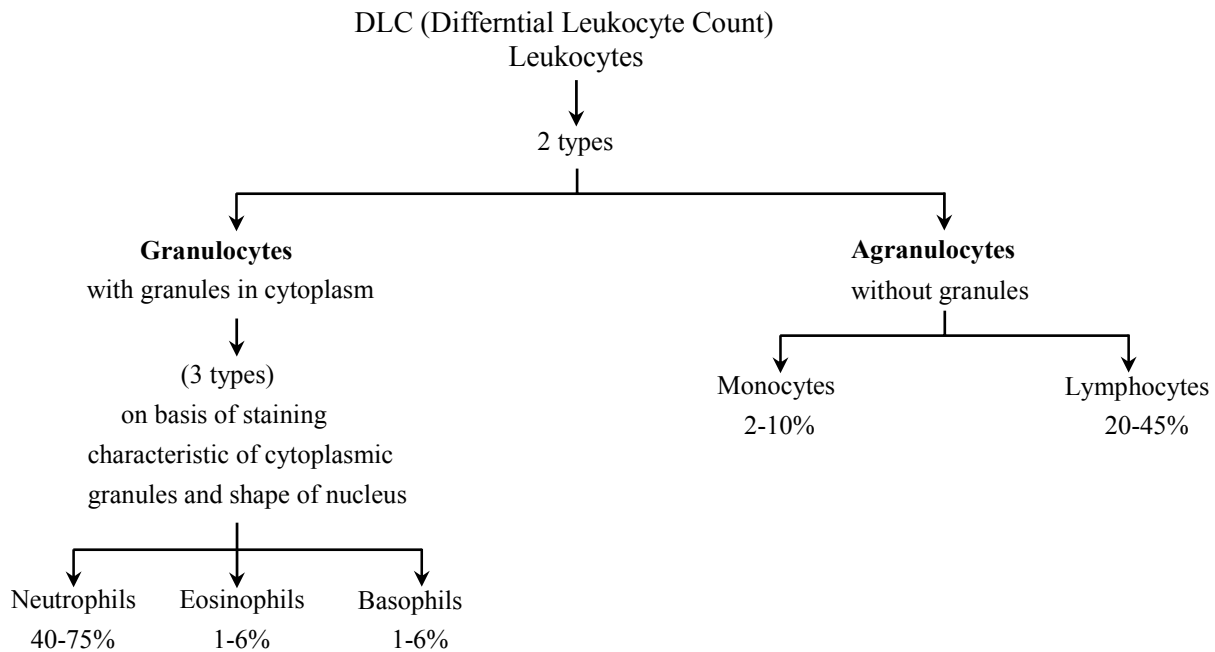




- 1% RBC are destroyed daily but in same number new RBC are entered in the blood.
- Destruction of RBC occur in spleen. So spleen is called **Grave yard** of RBC.
- Spleen stores excess blood corpuscles so it is called **Blood Bank of body**.
- In resting and slow flowing blood, the RBC form pile called **Roulaux** by adhering together due to surface tension. Fibrinogen favours rouleaux condtion.
- Minute bits of disintegrated red blood corpucles in known as **Haemoconia**
- Ghost of RBC is made up of its plasma membrane.

Table : Difference between different types of Leucocytes

<i>Character</i>	<i>Lymphocytes</i>	<i>Monocytes</i>	<i>Eosinophils</i>	<i>Basophils</i>	<i>Neutophils (Acidophils)</i>
Number/ percentage	20-25%	2-10%	2-3%	0.5-1%	60-65%
Granules in cytoplasm	Absent	Absent	Coarse	Coarse	Fine
Staining of cytoplasm	Basophilic	Basophilic	Eosinophilic	Basophilic	Neutrophilic
Nucleus	Rounded	Bean-shaped	Bilobed	S-shaped 3-lobed	Multilobed
Site of Formation	Lymph nodes, spleen, thymus, tonsils, Peyer's patches, Bone marrow	Bone marrow	Bone marrow	Bone marrow	Bone marrow
Life span	Few days or even years	10-20 hours in the blood tissue, months or even years	4-8 hours in blood and 4 to 5 days in tissue	4-8 hours in blood and 4 to 5 days in tissue	4-8 hours in blood and 4 to 5 days in tissue
Function	Antibody formation	Phagocytic	Important role in immunity anti-allergic	Secretion of heparin, histamine and serotonin	Phagocytic



LEUCOCYTES (WBC) ::

- WBC (White Blood Corpuscles) are also called as **leucocytes** because they are colourless. **TLC** = Total leucocyte count. Number of WBC/mm³ → 8000 – 11000/mm³

Leucocytosis :- Increase in TLC. This condition occur in Bacterial & Viral infection.

Leucocytopenia :- Decrease in TLC. Normally TLC increases in Bacterial & Viral infection but in typhoid & AIDS, TLC decreases.

Leukemia :- Abnormal increase in TLC (more than 1 Lakh) it is called as blood cancer.

- **On the basis of nucleus & nature of cytoplasm, Leucocyte are of 2 types.**

Granulocytes

- In their cytoplasm granules are present which can be stained by specific dye.
- Nucleus is multilobed and lobes are interconnected by protoplasmic strand.
- Due to presence of lobed nucleus they are called as polymorphonuclear WBC.
- Produced in Bone marrow

They are (i) Acidophils, (ii) Basophils & (iii) Neutrophils

Agranulocytes

- Cytoplasm is clear & granular
- Nucleus do not divide in lobes so called as Mononuclear WBC.
- Produced in Bone marrow

They are of 2 types (i) Monocytes (ii) Lymphocytes

ACIDOPHILS/EOSINOPHILS

- Amoeboid in shape.
- Size 10-14 μ



- Life span 4-8 hrs in blood
- In their cytoplasm acidophilic granules are present which can be stained by acidic dye Eosin.
- Nucleus is bilobed
- They protect body against allergy & parasitic infection.
- In allergy they synthesize **histamine**.
- In parasitic infection they act as lysosome. They attach with the surface or body wall of parasite and synthesize enzymes which dissolve body wall of parasite & destroy them.
- Increase in number of acidophils condition is eosinophilia which occurs in Taeniasis, Ascariasis, Hay fever (parasitic infection)

BASOPHILS

- Minimum in number
- Amoeboidal in shape
- Size 8 -10 μ
- Smallest granulocytes
- Life span 4-8 hrs in blood
- In their cytoplasm basophilic granules are present which can be stained with basic dye methylene blue.
- Nucleus is divided in 2 or 3 lobes. 'S' shaped.
- Their main function is to secrete & transport Heparin, Histamine & Serotonin produced in liver.

NEUTROPHILS/HETEROPHILS

- Maximum in number
- Amoeboid in shape
- Size 10-12 μ
- Life span – 4-8 hrs. in blood
- In their cytoplasm granules can be stained by any dye (acidic, neutral, basic).
- Nucleus is divided in 3-5 or more lobes. So maximum lobed nucleus is present in Neutrophils.
- Counting of lobes of Neutrophils is called **Arneth count**.
- They are active, motile WBC
- They can squeeze & comes out from the wall of blood capillaries in Tissue. This phenomenon is called **Diapedesis**.
- Phagocytic in nature
- Destroy Bacteria & Viruses by phagocytosis.
- Due to their smaller size & Phagocytic nature they are called **Microphice man**.
- Help in sex detection. In female neutrophils barr body is attached with lobe of nucleus which is formed by the modification of x chromosomes.
- barr body is absent in male.



MONOCYTES

- Size 12-20 μ
- Largest Blood Corpuscles.
- Life span-In blood 10-20 hours but in connective tissue it may be week/month.
- Nucleus kidney shaped/ bean shaped.
- Power of Diapedesis is present.
- Active motile WBC.
- Phagocytic nature.
- Destroy Bacteria & Viruses by phagocytosis so called **Macropoliceman**.
- Also called **scavenger** of blood because they engulf damaged or dead & minute bits of blood corpuscles.

LYMPHOCYTES

- Amoeboid in shape.
- Size 6-16 μ (smallest WBC)
- Life span in blood less than 10 days but in connective tissue it may be month/year/whole life
- Large nucleus is present.
- Lymphocytes are of 2 types.

T-LYMPHOCYTES

- Produced in bone marrow but mature in thymus gland. On the basis of function T-Lymphocytes are of 4 types
 1. T-Killer/Cytotoxic : - Direct kill Bacteria or Viruses
 2. T-Helper : - Stimulate B-lymphocytes to produce antibody.
 3. T-Suppressor : - Suppress T killer & protect immune system.
 4. T-memory : - Stores profile of bacteria or virus or protein.

B-LYMPHOCYTES

- Produced in bone marrow and mature in bone marrow. Its function is to produce, synthesize & transport antibodies

PLATELETS ::

- Also known as Thrombocytes
- Found only in mammals while in other vertebrates, Spindle corpuscles are present which perform same function.
- They are non nucleated and derived from **Megakaryocyte** cells of bone marrow.
- In shape platelets are disc like, oval shaped or biconvex.
- While spindle corpuscles are spindle in shape & round nucleus is present in the centre.
- In their cytoplasm basophilic granules are present which can be stained by methylene blue.



- Maximum part of cytoplasm is composed of contractile protein **Thrombostenin**.
- Size 2-3 μ
- Life span – 2-4/5 days
- Count – 1.5-4.5 lakh/mm³
- Decrease in number of Blood Platelets is called **Thrombocytopenia**.
- Critical count of Thromocytes is 40,000/mm³. If number is less than critical count then red spot or rashes appears on the skin called **Purpura disease**.

Function

- Repair endothelium of blood vascular system by the formation of platelet plug because they have tendency to attach on gelatinous or mucilaginous surface.
- Synthesize Thromoboplastin which help in blood clotting.
- Synthesize serotonin.

BLOOD CLOTTING ::

- Blood flows from cut or wound but after some times it stops automatically. It is called clotting of blood.
- Bleeding time 1-3 min.
Clotting time 2-8 min.
Some times clots are also formed in intact blood vessels which are of 2 types.

Thrombus Clot

- Static clots which grow bigger & ultimately block the blood vessels.
- If this clot is formed in the coronary vessels then called as Coronary Thrombosis which can cause heart attack.
- If form in brain, then called as Cephalic Thrombus causes paralysis.

Embolus clot

- Moving clots which flow with blood & ultimately dissolve in blood.
- More harmful due to their moving nature.

Machanism of blood clotting

(Enzymes Cascade theory)

- Proposed by **Macfarlane & Co-workers**.
- According to this theory there are 3 steps in blood clotting.

1. Releasing of Thromboplastin-

- Injured tissue synthesize exothrom hoplastin and platelets synthesize endothromboplastin.
- Both these thromboplastin react with plasma proteins in the presence of Ca⁺⁺ ions to form **Prothrombinase enzymes**. (Thrombokinase)
- This enzymes inactivate Heparin. (Antineparin)



2. Conversion of Prothrombin into Thrombin

- Prothrombinase enzymes convert inactive prothrombin into active Thrombin in the presence of Ca^{++} ion.

3. Conversion of fibrinogen into fibrin

- Fibrinogen is soluble protein of plasma. Thrombin protein polymerise monomers of fibrinogen to form insoluble fibrous protein fibrin.
- Fibrin form network on cut in which blood corpuscles got trapped. This form clotting of blood.
- After clotting a pale yellow liquid oozes from clot called **Serum**. In which antibodies are found.

Blood	–	Corpuscles	=	Plasma
Plasma	–	fibrinogen and large protein	=	Serum

Clotting Factors :-

- 13 factors help in blood clotting.
- These factors are mainly produced in liver.
- Vitamin K is required in the synthesis of these clotting factors.
- These factors are represented in Roman number.
- I – Fibrinogen
- II – Prothrombin
- III – Thromboplastin
- IV – Ca^{+2} (cofactor in each step of blood clotting)
- V – Proaccelerin
- VI – Accelerin (Rejected)
- VII – Proconvertein
- VIII – AHG Anti Haemophelic Globin (Absent in Haemophilia-A)
- IX – Christmas factor
- X – Stuart factor
- XI – PTA (Plasma Thromboplastin Antecedent)
- XII – Hageman factor
- XIII – FSF Factors (Fibrin stabilizing factor) (Laki Lor and factor).
- Other natural anticoagulants are
 - Hirudin – found in leech.
 - Anophelin – found in female Anophelese.
 - Lampredin – found in Peteromyzon (Lamprey)
 - Cumerin – obtain from plants
 - Warfarin – obtain from plants
- To collect blood in bottle in blood bank artificial anticoagulants are used like
 - Sodium citrate
 - Sodium oxalate
 - EDTA (Ethylene diamine tetra acetic acid)
 - These chemicals act as Calcium binding units and remove Ca^{+2} ions from blood.

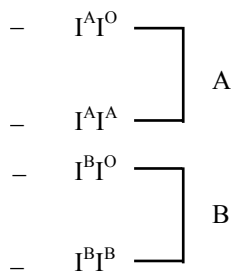


Blood Groups

- Antigen of blood groups is present on the surface of RBC also called as **agglutinogen**.
- Antibody for blood group antigen is present in serum (Plasma) called **agglutinin**.
- Antigen & Antibody are special type of **glycoproteins**.
- Blood groups are of 4 type A, B, AB, O
- A, B, O discovered by **Landsteiner**.
- AB discovered by Decastello & Struli.

Blood groups	Antigen	Antibody	Receive	Donate
A	A	b	A, O	A, AB
B	B	a	B, O	B, AB
AB	A, B	-	A, B, AB, O	AB
O	-	ab	O	A, B, AB, O

- Blood group O is universal donar & Blood group is **AB** is universal acceptor.
- Blood groups are example of **multiple alleles**.
- For gene of blood group 3 alternatives are present.
- Gene A & B are dominant gene. They can give their expression in homozygous and hetrozgous condition so blood groups A & B are due to dominant gene A&B



- Gene O is recessive gene which gives its expression in homozygous condition. Blood Group O is due to recessive gene.
- $I^O I^O$
- Blood group AB is an example of co-dominance in which both dominant gene A&B are present.
- $I^A I^B$ AB

**RH FACTOR ::**

- Discovered by **Landsteiner & Weiner** in Rhesus monkey.
- Rh antigen is due to dominant gene. So if one of the gamete possess gene of Rh factor, its off spring will be always Rh + Ve
- If antigen is present then Rh⁺
- If antigen is absent then Rh⁻
- In India % ratio of Rh is
 - Rh⁺ - 97%
 - Rh⁻ - 3%
- In World
 - Rh⁺ - 80%
 - Rh⁻ - 20%
- In Rh⁺ antibody is absent for this antigen
- Rh antibody is also absent in Rh⁻ blood But
 1. If Rh⁺ blood is transfused to Rh⁻ then 1st blood transfusion complete successfully but during Ist blood transfusion Rh antibodies are formed in receiver's blood so in next blood transfusion. agglutination of blood takes place.
 2. If mother is Rh⁻ & father is Rh⁺ then offspring is also Rh⁺ In this case 1st pregnancy is completely successful but during at the time 1st delivery Rh antibody is formed in mother's blood due to damaged blood vessel so in next pregnancy death of foetus will occur in the earilier stage due to agglutination of blood called **erythroblastosis foetalis**.
- To destroy Rh antibody medicines are used like **Rhogam, Rholin, Anti D**.

Muscular Tissue**Origin**

- It develop from the mesoderm of embryo.

Special property

- **Contractibility** is the special property of muscular tissue. The cells of muscular tissue can shorten considerably and return to original relaxed state. The muscle cells contract in a definate direction.

Functions of muscular tissue

- Muscles support the bone and other structure.
 - Muscles are responsible for heart beat production of sound, etc.
 - Muscles brings movements of the body parts and locomotion of individual.
 - Muscles are required for delivering a baby.
- ⇒ 40% to 50% of body weight is contributed by muscles.

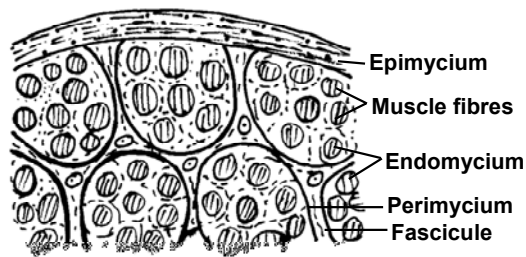


Fig. T.S. Muscle

Types of muscles

Muscles are of three types

Striated muscles

Unstriated muscles

Cardiac muscles

Striated Muscles

Structure

- Striated muscle fibre is also called striated, skeletal or voluntary muscle fibre.
- These muscle fibres occur in bundles and are attached to the skeleton.
- Each muscle fibre is surrounded externally by a delicate membrane **sarcolemma**.
- In each fibre many nuclei appear at irregular intervals, so each fibre is **syncytial**.
- The cytoplasm (Sarcoplasm) of each fibre possesses a large number of myofibrils which are tightly packed.
- Each myofibril possesses dark and light bands alternating with each other.

Detailed structure of a myofibril

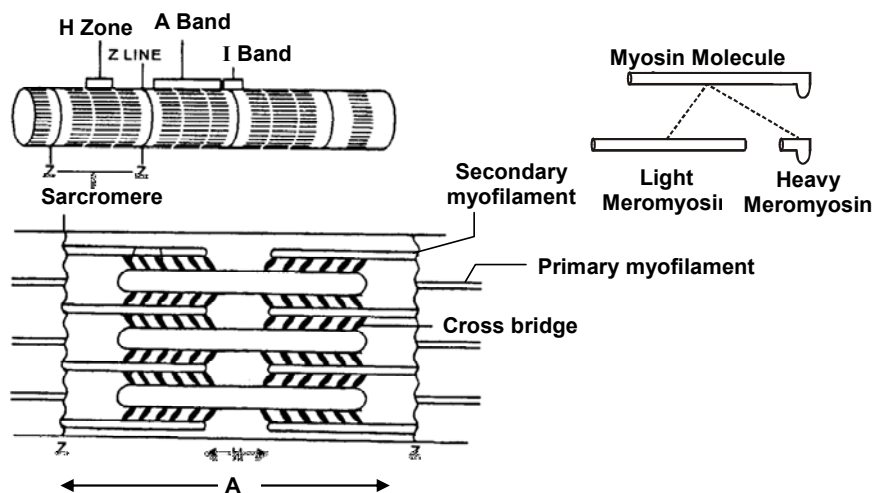


Fig. Structure of Vertebrate Striated Muscle at Magnification

- The dark band of myofibril is called **A-bands** (Anisotropic bands). Each A band possesses a light zone called **H-zone** or **Henson's membrane** in the middle.
- The light band of myofibril is called **I-bands** (Isotropic bands). Each I-band possesses a thin dark z-disc or Krause's membrane in the middle.
- ⇒ Krause's membrane is also called **Dobie's line** or **Zwischencheibe line**.
The portion between two discs is called a **sarcomere**. **Sarcomeres are the functional units of myofibrils.**

- Each sarcomere has two types of myofilaments; a coarse or primary and fine or secondary myofilaments arranged longitudinally. The primary myofilament is made of a protein called **myosin** whereas secondary myofilament is made up of 3 protein **actin** tropomyosin, troponin. Besides actin and myosin muscle fibre also contain **calcium ion, a phosphate** and adenosine triphosphate (ATP)

The primary filament remain confined to A bands only.

Location

Striated muscles are found in the muscle of limbs, tongue, pharynx, beginning of oesophagus, etc.

Function

These muscles are under control of will.

Unstriated muscle

Structure

- Unstriated muscle fibre is also called smooth, involuntary, unstriped or visceral muscles.
- Each fibre is elongated or spindle shaped, having single oval nucleus surrounded by cytoplasm.
- Each muscle fibre possess longitudinally myofibrils arranged.
- The fibre is enclosed by plasma membrane and unlike striated muscle there is no sarcolemma.
- Several of muscles fibre are joined together in bundles by loose connective tissue.

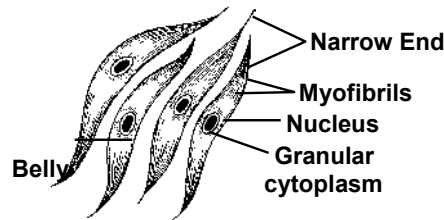


Fig. Smooth Muscle

Location

Unstriated muscles are found in stomach, intestine, lungs, urinary bladder, urinogenital tract, iris of eye, dermis of skin, posterior part of oesophagus and arrector pilli muscles of hairs.

Function

These muscle fibre helps in peristalsis. It causes slow and prolonged contraction which is involuntary i.e. not under control of will but are controlled by autonomic nervous system.

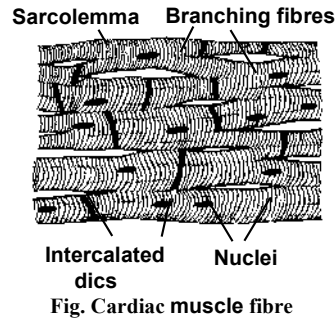
Single-unit smooth muscles	Multi-unit smooth muscles
(i) They have number of muscle fibres closely joined together.	(i) They have number of muscle fibres not so closely joined.
(ii) all the fibres contract together as a single unit, automatically and rhythmically. e.g. Walls of hollow visceral organs like stomach, intestine, urinary balder etc.	(ii) The individual fibres contract s separate units more of less as independent muscle e.g. hair roots, and on the walls of large blood vessels.



Cardiac muscles

Structure

Cardiac muscle fibres show character of both striped and unstriped muscles, fibres in some characteristic, but also have some peculiar characters of its own.



Similarities with striated muscle fibres :

Cylindrical, high vascularization, having more mitochondria and glycogen granules in the sarcoplasm; and having light and dark bands.

Similarities with smooth muscle fibres

Uninucleate; involuntary, covered by plasma membrane.

Unique character

- Cardiac muscle fibres are joined with each other by flat dense zig-zag junctions, called **intercalated discs** or booster rings.
- Cardiac muscle fibre is supplied by both central nervous system and autonomic nervous system.
- These muscles never get fatigued, blood capillaries penetrate the cardiac muscle fibres. They have the property of contraction even when they are isolated from the body temporarily.
- Shows long refractory period.

Location :

These muscle fibres are found in the wall of heart and have very rich blood supply.

**Differences between striated, non striated and cardiac muscles.**

S.No.	Striped	Unstriped	Cardiac
1.	Occur in the body wall, limbs, tongue, pharynx and beginning of oesophagus	Occur in the wall of hollow viscera, iris of the eye and dermis of the skin.	Occur in the walls of heart, pulmonary veins and superior venacava.
2.	Have numerous mitochondria and glycogen granule	Have less numerous mitochondria and glycogen granules	Have numerous mitochondria and glycogen granules
3.	T-tubule system well developed	T-tubule system lacking	T-tubule system well developed
4.	No intercalated discs	No intercalated discs	Intercalated discs occur between the end of fibres.
5.	Voluntary	Involuntary	Involuntary
6.	Fibres unbranched	Fibres unbranched	Fibres join by short oblique bridges
7.	Blood supply is abundant, capillaries lie on the surface of fibres	Blood supply is scanty, capillaries lie on the surface of fibres	Blood supply is abundant, capillaries penetrate the fibres, Lymphatic capillaries also present
8.	Multinucleate, nuclei just near the sarcolemma	Uninucleate, nucleus at the centre	Mostly uninucleate, Nucleus at the centre.
9.	Myofibrils large and prominent, show distinct alternating light and dark cross bands, hence striped	Myofibrils indistinct and do not have light and dark bands, hence unstriped	My ofibrils distinct and with faint alternating light and dark bands
10.	Also called striated, skeletal and voluntary muscle fibres	Also called non-striated, smooth, visceral and involuntary muscle fibres	Also called heart muscle Fibres
11.	Contract quickly and power-fully, but cannot maintain contraction for a long time, hence soon get fatigued.	Contract slowly and mildly, but can remain contracted for a long time, are not fatigued.	Contract quickly, Powerfully and rhythmically, non-fatigue. indefatigable
12.	Innervated by motor nerves from central nervous system (neurogenic)	Innervated by nerves from autonomic nervous system (neurogenic)	Innervated by nerves from central and autonomic nervous systems (neurogenic + Myogenic)



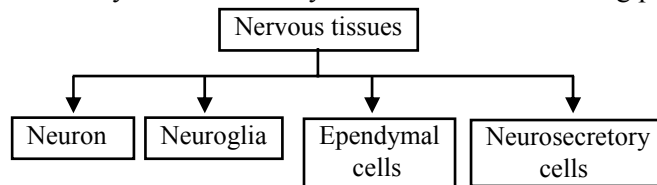
Nervous Tissue

Origin

Nervous tissues originates from ectoderm of embryo.

Special properties

- The special properties of the cells of nervous tissues are **excitability** and **conductivity**.
 - The cells of nervous tissues are specialized for receiving stimuli and transmitting message.
- These tissue forms nervous system of the body and include the following parts :



Composition

Nervous tissue is formed of four types of cells –

- Neurons
- Neuroglia
- Neuro-secretory cells
- Ependymal cells

Neurons

- A neuron is a nerve cell with all its branches, Neuron is formed from neuroblast.
- **It is structural and functional unit of nervous system.**

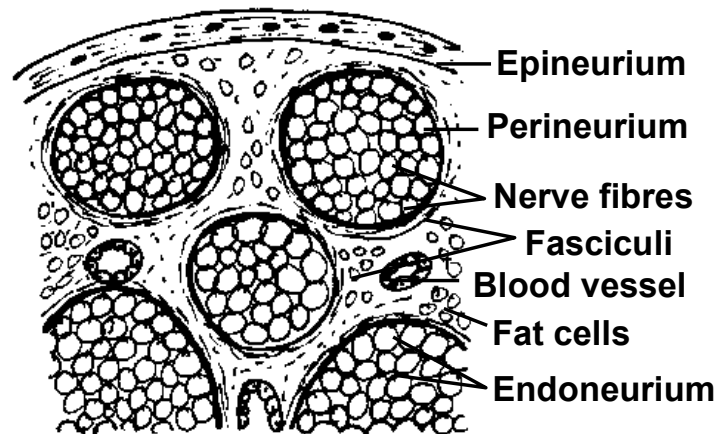
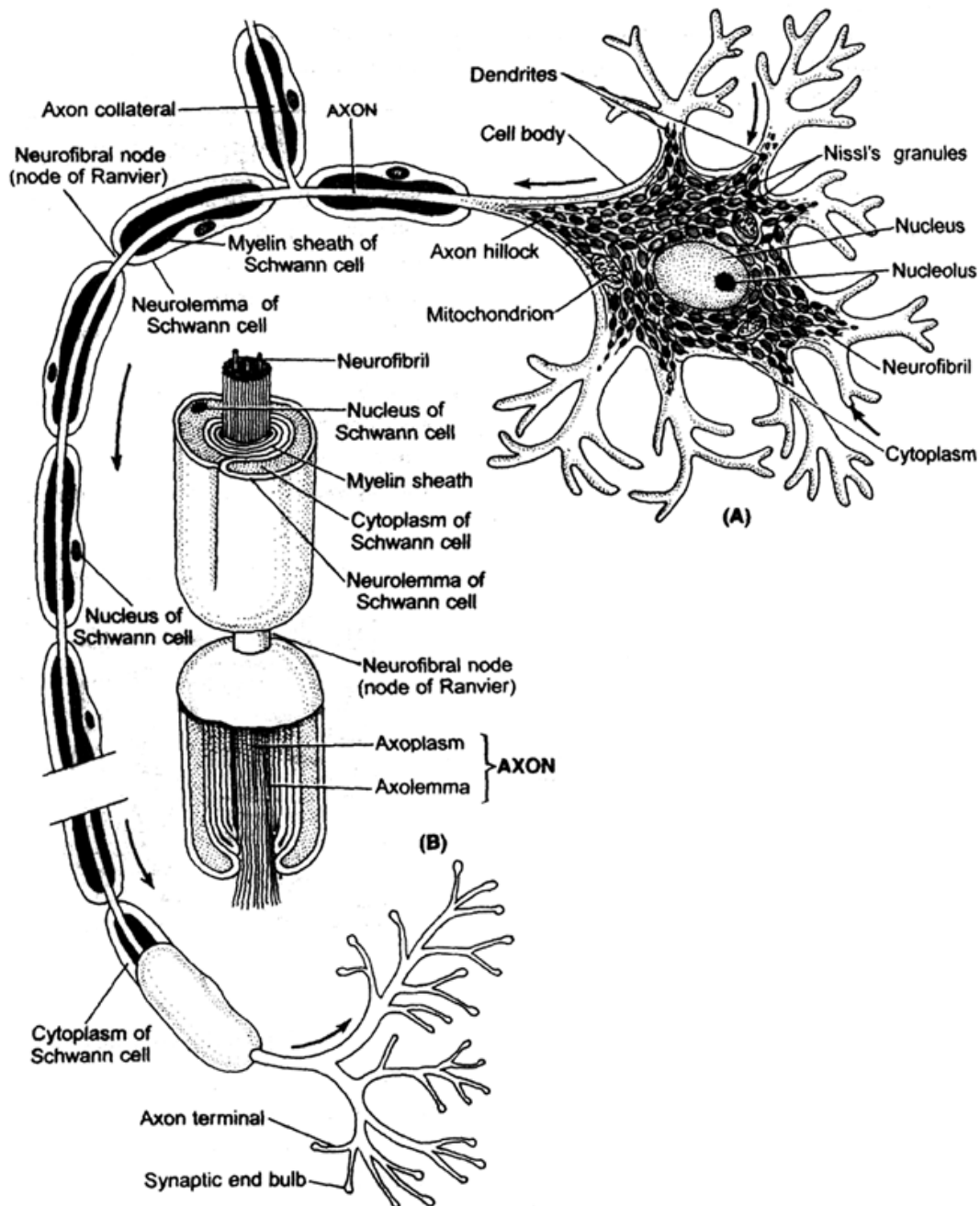


Fig. T.S. of

⇒ Neuron is the longest cell of the body.

Structure : Neurons is formed of two parts –

- (A) Cyton (B) Nerve processes



(A) Basic Structure of a neuron (B) Section through a myelinated fibre

Cyton

- Cyton is also called cell body or soma, its shape is variable.
- Its cytoplasm is granular called neuroplasm, within neuroplasm has a prominent spherical nucleus golgibodies, endoplasmic reticulum lysosome, fat globules, Nissl's granules and neurofibril is found.
- Nissl's granules are comparatively large and irregular masses of ribosomes and rough endoplasmic reticulum. **It is believed that nissil's granules synthesize protein in the cell.** Nissl's granules are made up of m-RNA, ER, Ribosomes and has affinity for basic dyes.

A mature neuron cannot divide.



Nerve processes

The nerve processes are also called neurites. Nerve processes can be divided into two parts-

- (a) Dendrites (b) Axon

Dendrites -

Dendrites may be one or several. It is branched structure.

Axon -

- It is single, long and cylindrical process whose main function is to conduct the nerve impulses away from the cyton, so, axon is efferent in nature.
- It is the longest nerve process of a neuron.

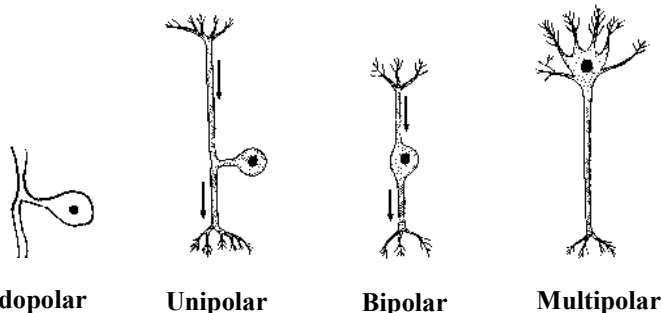
Note :

- Giant squid (loligo) has axon of about 1500 μm in diameter.
- Neurons with very long axon is called golgi type I.
- Axon possess only neuro-fibrils. (Nissls Granule, Golgi body, Ribosome, fat globules are absent). The part of cyton from where the axon arises is called **axon hillock**. Some axon also give rise to side branches called **collateral fibres**.
- The plasmalemma of axon is called **axolemma** whereas cytoplasm is called **axoplasm**.
- The axon ends in a group of branched, the **terminal arborization**, ends of terminal arborization possess knob like structure called **synaptic knob** or **synaptic buttons**.

Synapse

- Synaptic knobs comes to lie very close to the dendrons of next neuron to form the synapses. There is a microscopic gap of about 200 \AA called **synaptic cleft**.
 - The nerve impulses are transmitted from axon to dendron with the help of chemical called **neurotransmitters** which is either acetylcholine or adrenalin (epinephrine) or Electrical symapse (with synaptic cleft of 2 nm)
- ⇒ Acetylcholine or adrenaline is produced by the secretory vesicles of the synaptic knobs.

Types of neurons



On the basis of number of dendron and axon neurons are of 3 types -

- **Unipolar neuron** - The neuron having a single process the axon are called unipolar neuron. e.g. Unipolar nervous system occurs in embryo.
- **Bipolar neuron** - The neuron having one dendron and an axon at the opposite pole of the cell are known as **bipolar neuron**. e.g. Bipolar neuron occur in retina of eye, Olfactory epithelium, Organ of Corti, Taste bonds.



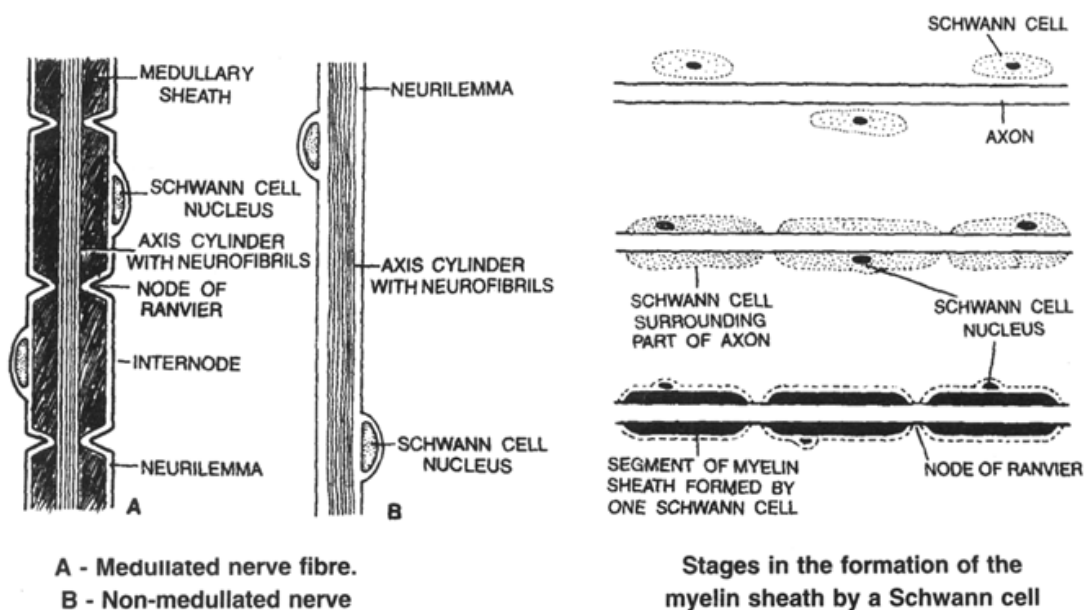
- **Multipolar neuron** : The neuron which have many dendrons and one axon are termed as **multipolar neuron**.

e.g. Multipolar neuron occur in nervous system of adults.

On the basis of functions neurons are of 3 types-

- **Sensory or afferent neuron** - They connect Sensory organs with central nervous system and brings sensory impulses into it.
- **Motor or efferent neuron** - They connect central nervous system with the effectors. (muscles and glands) and carry motor impulses to them.
- **Interneurons or adjustor neuron** - They are present in the central nervous system (Brain and spinal cord) and connect two or more neurons for distant transmission of impulses.

Nerve fibres



An axon of a neuron is covered with one or two sheaths.

On the basis of number of sheaths on nerve fibre, nerve fibres are of two types -

- Medullated or myelinated nerve fibre
- Non medullary nerve fibre

Medullated or myelinated nerve fibre

- In these nerve fibres around the nerve a sheath of fatty substance is formed which is termed as medullary sheath or myelin sheath.
- The medullary sheath is not continuous and point of absence of medullary sheath is called **nodes of Ranvier**. The part of medullated nerve fibre between two adjacent nodes is called an **internode**. Medullary sheath forms an insulating coat and prevents loss of energy during conduction of nerve impulse.
- The medullary sheath and node of ranvier are surrounded by a transparent cellular outer covering known as neurolemma of **Schwann cell**.



- Just beneath the neurolemma a thin layer of cytoplasm lies, which contains nuclei to form Schwann cells (Sheath cells) at intervals. These nuclei are termed nuclei of Schwann cell.
- Medullated nerve fibre are found in brain spinal cord, cranial and spinal nerves. In the central nervous system, medullated nerve fibres form white matter.

Non-medullated (Non myelinated) nerve fibre

- In these nerve fibre no medullary sheath is found. The axon is surrounded by neurilemma and just below neurolemma a layer of cytoplasm containing nuclei at intervals is present. The node of Ranvier and internode are not present.
- The non medullated nerve fibres exists in autonomic nervous system.
- In central nervous system non medullated nerve fibre found in grey matter.

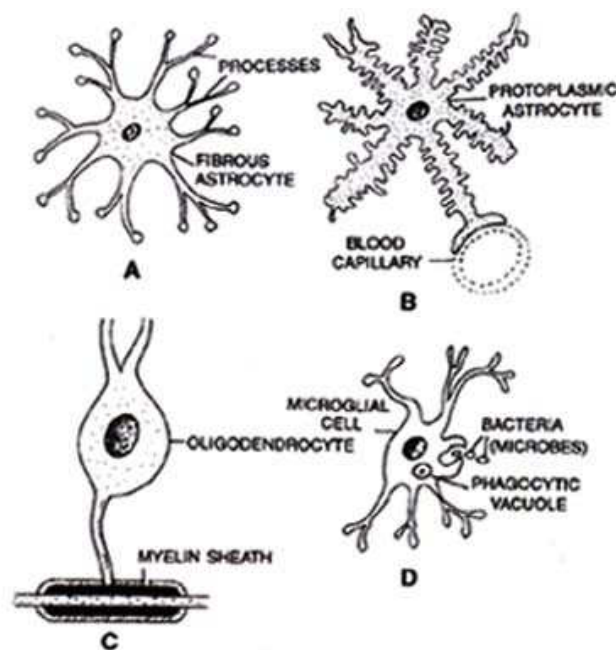
Functionally the nerve fibres are of two types :

- **Afferent or Sensory fibre** - Afferent fibre carries the sensory impulse from the receptor organs to the central nervous system (brain and spinal cord).
- **Efferent or motor fibre** - Efferent fibre carries impulses from the central nervous system to the various effector organs (muscles and glands).

Neuroglia or Glial Cells

- These are non nervous cells which lie between the neurons of CNS, ganglia and retina of the eye.
- These are many times (10 times approx) more numerous than neurons.

Types of neuroglial cells



Different kinds of neuroglial cells.

A. Fibrous astrocyte. B. Protoplasmic astrocyte C. Oligodendrocyte. D. Microglial cell.



Neuroglia cells are of following types

- Microglia cell - These are spindle shaped small cells.
- Astrocytes - These are highly branched.
- Oligodendrocytes - These have few branched processes which resemble dendrons of the neuron.

Functions

- These act as packing cells between neurons.
- These provide nutrition to neurons
- These act as phagocyte and consume micro organism.
- These help in memory process
- These insulate the adjoining neurons.

Ependymal cells

These cells form an epithelium called **ependyma** that lines the ventricles of brain and the central canal of the spinal cord. The cells are generally ciliated.

Neurosecretory cells

These are special type of neurons of the hypothalamus of brain. These are endocrine in function and release neurohormone (releasing factor) through portal system to anterior most lobe of pituitary gland where they regulate secretion of hormones TSH, GH, LH, ACTH, FSH and Prolactin.